

Indian Society of
Critical Care Medicine (ISCCM)



Guidelines in Toxicology

Editors

Narendra Rungta
Rajesh Chandra Mishra
Banambar Ray
Parshotam Lal Gautam
Devi Prasad Samaddar
Prashant Kumar



CBSPD Dedicated to Education

CBS Publishers & Distributors Pvt Ltd



Acute Paraquat Poisoning

ABSTRACT

Poisoning by paraquat is one of the common toxicological problems with high case fatality rate. It is a nonselective herbicide. Paraquat is available as a 24% formulation in India. Paraquat toxicity leads to multi-organ failure mainly through the reactive oxygen species that are generated as it undergoes redox cycling. Acute kidney injury and pulmonary fibrosis are the major events leading to death. There is no specific antidote, and treatment is mainly supportive. Hemoperfusion and renal replacement therapy are usually attempted with variable results. Immunosuppressive therapy with steroids and cyclophosphamide is tried but there is not much strong evidence to support it. Antioxidants (acetylcysteine, salicylate, etc.) were used; however, there is sparse evidence from human trials to support their use evidence from human trials. Despite treatment with these agents, case fatality is still very high.

Keywords: Paraquat, Herbicide, acute kidney injury, Pulmonary fibrosis, Multi-organ failure, Immunosuppression, Hemoperfusion

INTRODUCTION AND EPIDEMIOLOGY

Paraquat (PQ) is a compound with chemical formula of "1,1'-dimethyl-4,4'-bipyridinium dichloride" is a nonselective herbicide being used since the 1960s. It is a fast-acting contact weed killer but is deactivated when it comes in contact with soil. However, ingestion of PQ is extremely toxic to humans with no specific antidote or effective treatment¹. Paraquat involves many organ systems, mainly lung, kidney and liver leading to multiorgan failure and death. In India it is available as paraquat dichloride (24% solution).

PQ ingestion leads to several tens of thousands deaths per year worldwide. Paraquat poisoning has been reported from various parts of India but only meager data is available and that too in the form of case reports or case series.²⁻⁴ PQ is not as common poisoning as organophosphorus, but is the leading cause of death owing to its high case fatality (>50%).¹ In a Malaysian study, incidence (2004–2015) of paraquat poisoning was recorded from the calls received at its national poison center. The most common age group involved in the poisoning was 20–39 years and in 62.8% of cases the ingestion was intentional.⁵ In a south Indian study from a tertiary care center², acute kidney injury was the most common manifestation and mortality was 72.7%.

Over the last more than 50 years, several methods have been tried to modify paraquat toxicity. Patients received hemoperfusion, haemodialysis⁶, immunosuppressants, and

antioxidants, but the outcome in paraquat poisoning still depends upon the dose of ingested toxin. In this article, we will be reviewing the adverse effects, diagnostic and therapeutic approaches for patients with acute paraquat intoxication.

MECHANISM OF PARAQUAT TOXICITY

Kinetics

Oral ingestion of paraquat is the most common route of toxicity. It can be absorbed through the skin (especially if damaged), mucous membranes, eyes or via the inhalational route, but symptoms are often delayed. Localized skin damage or dermatitis, eye injury and epistaxis occur frequently among patients exposed to paraquat. The median lethal dose is 3–5 grams. Swallowing^{20–30} mL (mouthful or two) of 20% paraquat is usually lethal, and even 10 mL can cause significant illness.⁷ Once ingested, less than 5% is absorbed through the GI tract. Recent food ingestion delays the absorption of the toxin. Peak plasma and lung concentration are reached within 1–2 hours and 5–7 hours respectively after ingestion. The volume of distribution is approximately 2.75 L per kg, and it follows a multicompartment distribution model. Ninety percent of the PQ is excreted by kidneys in 12–24 hours. Half-life is 12 hours with normal renal function, but it increases up to 120 hours as renal failure sets in.⁸

MECHANISM OF CRITICAL TOXICITY

Paraquat concentration in the lung increases continuously after a few hours of its ingestion. It keeps on increasing despite there being fall in plasma concentration of paraquat. It may be attributed to the endogenous polyamine transport system in type I and II alveolar cells, where it undergoes redox cycling and generates reactive oxygen species (ROS). These ROS are one of the several pathways through which paraquat toxicity occurs.

Paraquat (PQ) is reduced to mono cation radical (PQ⁺) in a reaction dependent on nicotinamide adenine dinucleotide (NADH), NADPH-cytochrome P450 reductase, and xanthine oxidase. PQ⁺ initiate injury to pneumocytes. The spontaneous reaction of PQ⁺ with molecular oxygen yields the superoxide radical (O₂⁻) and reversibly forms PQ⁺⁺. Peroxynitrite (ONOO⁻), a strong oxidant is formed after O₂⁻ combines with nitric oxide. These highly reactive oxygen species which are derived from various pathways lead to toxic insult to most of the organs.¹

ROS initiate an inflammatory process in organs including the lungs. It initiates inflammatory cell infiltration (Fig. 6.1). PQ also leads to mitochondrial damage, possibly due to an increase in its membrane permeability that leads to mitochondrial swelling. PQ also increase free iron from ferritin.⁹ These pathophysiological pathways triggered the use of antioxidants and deferoxamine in the management of PQ toxicity.

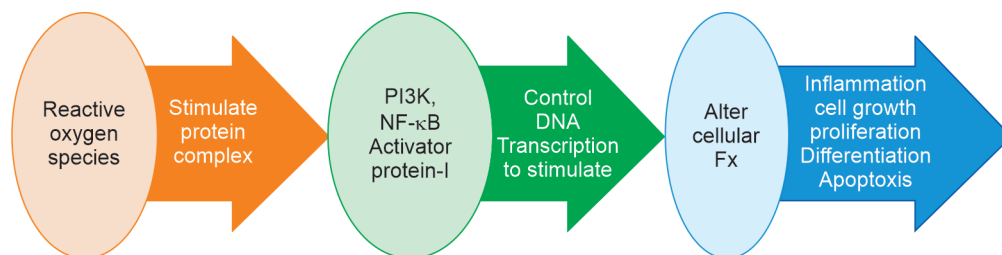


Fig. 6.1: Reactive oxygen species (ROS) mediated inflammatory cascade

PATHOLOGICAL PROCESSES IN THE MAJOR TARGET ORGANS

Paraquat toxicity is most severe in the lungs inflammatory process and cellular damage involve other organs too. In lungs it leads to apoptosis of affected cells in a process that is initiated with diffuse alveolitis. Initial pulmonary edema leads to proliferative stage followed by lung fibrosis.

Apart from lungs ROS affects proximal convoluted tubules of the kidneys, inflammation leading to necrosis. Hepatocytes injury leads to liver damage, associated with damage to mitochondria and endoplasmic reticulum.

CLINICAL FEATURES OF ACUTE PARAQUAT TOXICITY

Acute paraquat intoxication is usually asymptomatic in the early stage. Patients may present with irritation and numbness of the tongue and oral mucosa. Patients may also develop ulcerative lesions over tongue that may have occasional bleeding (Paraquat tongue). Severity and extent of oral and tongue lesions are not of any prognostic value as they also appear in patients who spit PQ out without swallowing. GI tract toxicity is universal after ingestion. Like corrosives, PQ ingestion leads to mucosal lesion in the pharynx and esophagus and it may lead to mediastinitis, pneumomediastinum or perforation of esophagus or stomach.

The systemic manifestation of paraquat toxicity depends upon the quantity ingested (Table 6.1), patient's age (>50 years), and presence of comorbidities (kidney disease). Patients, who had ingested more than 50 mL of 20% PQ solution may present with hypoxia and shock with multi-organ involvement. These patients have fulminant course and death ensues in few hours to few days.

PQ ingestion of 10–50 mL is referred to as moderate to severe poisoning. These patients usually show renal involvement initially over 2–6 days. Hypoxia starts after 3–7 days and worsens gradually and the patient dies of severe hypoxia due to lung fibrosis in 4–6 weeks.

<i>Severity</i>	<i>Ingested amount (mL) of PQ 24%</i>	<i>Ingested PQ (mg/kg body weight)</i>	<i>Sign and symptoms</i>	<i>Time since ingestion</i>
Mild or asymptomatic	<10	<20	No symptoms or oral ulcers/ mild GI symptoms	Immediate
Moderate to severe	10–50	20–40	Irritation and numbness of tongue and mouth, Nausea, vomiting, abdominal pain, diarrhea	Day 1
			Oliguria	Day 3–4
			Dyspnea and tachypnea	Day 3–4
			Acute respiratory illness	Days to weeks

Contd.

Severity	Ingested amount (mL) of PQ 24%	Ingested PQ (mg/kg body weight)	Sign and symptoms	Time since ingestion
Severe/ acute fulminant toxicity	>50	>40	Oral mucosal and pharyngeal pain and burns, with chest pain (Esophageal injury)	Day 1
			Agitation and confusion (Due to pain and hypoxia)	Day 1
			Burning skin sensation (Indicate poor prognosis)	Day 1
			Decreased urine flow progressing to anuria	Days 1–3
			Tachycardia, hypotension, and cardiovascular collapse Pulmonary oedema with respiratory distress and rapid respiratory failure, hepatic involvement	Within 48 hours

INVESTIGATION

Qualitative Tests

Plasma and Urine Sodium Dithionate Test

Dithionate reduces PQ blue-colored substance in an alkaline medium if the urine paraquat levels are >1 mg/L and plasma paraquat levels are >2 mg/L. If urine turns blue then it indicates a very poor prognosis.^{11,12} Plasma PQ measurement is also useful both to confirm poisoning and predict prognosis.¹³ There are nomograms and formulae of plasma PQ concentrations to predict outcomes after toxin ingestion.^{14,15}

Routine Investigations

ABG, routine complete blood counts liver and kidney function tests including serum electrolytes should be done on admission and regular interval to guide the supportive treatment. We may do serum lipase, amylase if we suspect acute pancreatitis. Chest X-ray, and CT scans of the chest to detect pneumothorax, pneumomediastinum, and early fibrosis.

Management

There is no set protocol or guideline for the management of paraquat poisoning. In absence of an antidote supportive care is the mainstay of therapy. Various therapies are being used in the form of renal replacement therapies,^{16,17} immunosuppressants and antioxidants.

Resuscitation

Airway, breathing and circulation (ABC) should be assessed and general resuscitation should be done as routine protocol. Patients presenting early may be asymptomatic. Delayed presentations are common and patients may be tachypneic secondary to metabolic acidosis or

pulmonary complications (blood gas analysis and chest radiograph are important). Hypoxia needs to be treated only if oxygen saturation is less than 90%. Fluid resuscitation is to be done if signs of hypovolemia are present.

Prevention of Gastrointestinal Absorption

PQ is corrosive, so gastric lavage is a relative contraindication; however, a nasogastric tube should be inserted in patient presenting early (within 2–4 hours of ingestion). This tube can be used to administer activated charcoal (1–2 g/kg) or Fuller's earth (Multani Mitti). Later on, this tube can be used for enteral feeding.

Removal of Paraquat from the Blood

The peak time of plasma paraquat is 1–3 hours post-ingestion, and that of lung cells is 4–5 hours and nearly 90% of the paraquat disappears in the plasma 5–6 hours after ingestion. Ideally hemoperfusion (HP) and renal replacement therapies (RRT), should be started as early as possible, within 2–4 hours of ingestion, but should be used within 6 hours after that evidence of benefit is very much limited.^{3,10}

HP results in a more rapid reduction of paraquat plasma levels than haemodialysis and early initiation is important for survival. CVVH may improve survival, reduce organ dysfunction and prolong the survival time for patients to receive additional treatments.^{18–21} This effect of HP in PQ toxicity is time limited as kidney start clearing the toxin in initial 6–12 hours so plasma levels will be lower. Moreover, this elimination from HP will not protect the impact of the toxin on the lung.^{22–24} As per small observational studies there is some mortality benefit of adding CVVH but the long term outcome and mortality rate did not improve.^{25–27} At best CVVH may give time for novel therapies like ECMO along with lung transplant by preventing early death.

In patients who are presenting early, HP with monitoring of the urine paraquat concentration can reduce the early mortality. Urine PQ need to be monitored after each HP session and this to be continued till urine PQ concentration is negative. Urine PQ measurements should be repeated again after 24 hours. If negative till 48 hours then may plan to stop HP. There are few observational studies to suggest mortality benefits of CVVH too along with HP but there are no improvements in long-term survival.

Immunosuppressant Therapy and Antioxidants

As discussed earlier PQ initiates an inflammatory response through ROS. Immunosuppressants and antioxidants may intervene this part of the cascade and prevent further organ damage.

For more severe poisoning, patients receiving both glucocorticoids (methylprednisolone 1 gram) for 3 days and cyclophosphamide 1 gram for 2 days may have a lower death rate.

Cyclophosphamide should be added along with steroids for first 2 days.

Antioxidants e.g. vit E, vit C, n-acetyl cysteine (NAC), deferoxamine, salicylates act as free radical scavengers. vit E and salicylates also inhibit NF- κ B activation and thus transcription of proinflammatory mediators high-dose long-term antioxidants could potentially be a critical component improving the survival rate in severe paraquat poisoning. Limiting oxygen therapy for patients with a PaO₂ >50 mm Hg can prevent free radical formation.^{28–30}

Role of Mechanical Ventilation

Mechanical ventilation (MV) has a role for respiratory support. Patients requiring MV usually have a poor prognosis. Early MV may further worsen the fibrosis. Controlled

hypoxia may have no effect in worsening paraquat induced pulmonary injury and oxygen supplementation may worsen the lung injury.³¹⁻³³ Noninvasive or invasive ventilation may be used as a bridge to extracorporeal therapies and lung transplant later.

Antifibrotic Agents

Seifirad et al.³⁴ and Sanaei-Zadeh³⁵ suggested that pirfenidone may decrease pulmonary fibrosis after PQ toxicity. But there are no controlled human trials and pirfenidone administration is debatable.

Extracorporeal Membrane Oxygenation

ECMO can be used for PQ victims, though should only be used when lung transplant can be offered. ECMO can be used in early or late stages. In early stages its mainly used for both cardiac and respiratory support (VA) and in late stages, it is mainly for respiratory support (VA)with a bridge to transplant plan. Survival rate is better in those patients who needed ECMO at a later stage in contrast to higher mortality in patients needing ECMO in early stage(less than a week).³⁶⁻³⁸

FUTURE RESEARCH

Paraquat is a leading cause of fatal herbicide poisoning. A recent understanding in its kinetics and pathophysiology has provided us with some hope to counter the toxic effect. The use of evolving hemoperfusion techniques, which can be applied beyond 2-4 hours of ingestion can decrease the toxicity. Studies are needed for the use of potent immunosuppressive drugs, their dose and duration can improve morbidity and mortality. Further studies are also needed for the use of ECMO and lung transplant in sicker cases.

PARAQUAT BRANDS IN INDIA



Error! Error!



CONCLUSION

Pesticide poisoning is still a common method of suicide in India. In the absence of definitive treatment and high fatality with paraquat ingestion, it is important to have stringent legislative restrictions on its uses. Early use of hemoperfusion and renal replacement therapy may limit its toxicity. Immunosuppressants and antioxidants may have some role in preventing further injury. As very little human data is available, further studies are needed to guide the timing, choice of doses, duration and combinations of these drugs.

REFERENCES

1. Gawarammana IB, Buckley NA. Medical management of paraquat ingestion. *Br J Clin Pharmacol*. 2011;72(5):745–57.
2. Ravichandran R, Amalnath D, Shaha KK, et al. Paraquat Poisoning: A Retrospective Study of 55 Patients From a Tertiary Care Center in Southern India. *Indian J Crit Care Med*. 2020;24(3):155–9. doi:10.5005/jp-journals-10071-23369.
3. Rao R, Bhat R, Pathadka S, et al. Golden hours in severe paraquat poisoning-the role of early haemoperfusion therapy. *J Clin Diag Res* 2017;11(2):OC06. doi: 10.7860/ICDR/2017/24764.9166.
4. Sandhu JS, Dhiman A, Mahajan R, et al. Outcome of paraquat poisoning - a five year study. *Indian J Nephrol* 2003;13:64–8.
5. Leong YH, Ariff AM, Khan HRM, et al. Paraquat poisoning calls to the Malaysia National Poison Centre following its ban and subsequent restriction of the herbicide from 2004 to 2015. *J Forensic Leg Med*. 2018;56:16–20. doi:10.1016/j.jflm.2018.03.007.
6. Eizadi-Mood N, Jaberi D, Baruti Z, et al. The efficacy of hemodialysis on paraquat poisoning mortality: A systematic review and meta-analysis. *J Res Med Sci*. 2022;27:74. Published 2022 Sep 27. doi:10.4103/jrms.jrms_235_21
7. Wilks MF, Tomenson JA, Fernando R, et al. Formulation changes and time trends in outcome following paraquat ingestion in Sri Lanka. *Clin Toxicol (Phila)* 2011;49:21.
8. Kevin N. Baer. In *Encyclopedia of Toxicology (Second Edition)*, 2005 <https://www.sciencedirect.com/referencework/9780123694003/encyclopedia-of-toxicology>.

9. Gil HW, Hong JR, Jang SH, et al. Diagnostic and therapeutic approach for acute paraquat intoxication. *J Korean Med Sci.* 2014;29(11):1441–9. doi:10.3346/jkms.2014.29.11.1441
10. Kang MS, Gil HW, Yang JO, Lee EY, Hong SY. Comparison between kidney and haemoperfusion for paraquat elimination. *J Korean Med Sci.* 2009;24:156–60.
11. Koo JR, Yoon JW, Han SJ, et al. Rapid analysis of plasma paraquat using sodium dithionite as a predictor of outcome in acute paraquat poisoning. *Am J Med Sci* 2009;338(5):373–7.
12. Scherrmann JM, Houze P, Bismuth C, et al. Prognostic value of plasma and urine paraquat concentration. *Hum Toxicol.* 1987;6:91–3.
13. Proudfoot AT, Stewart MS, Levitt T, et al. Paraquat poisoning: significance of plasma paraquat concentrations. *Lancet.* 1979;2:330–2.
14. Hart TB, Nevitt A, Whitehead A. A new statistical approach to the prognostic significance of plasma paraquat concentrations. *Lancet.* 1984;2:1222–3.
15. Bismuth C, Dally S, Scherrmann JM, et al. [Paraquat poisoning. Prognostic and therapeutic evaluation in 28 cases] *Nouv Presse Med.* 1982;11:3239–44.
16. Iyyadurai R, Mohan J, Jose A, et al. Paraquat poisoning management. *Curr Med Issues* 2019;17:34–7.
17. Elenga N, Merlin C, Le Guern R, et al. Clinical features and prognosis of paraquat poisoning in French Guiana: A review of 62 cases. *Medicine (Baltimore)* 2018;97:e9621.
18. Li A, Li W, Hao F, et al. Early Stage Blood Purification for Paraquat Poisoning: A Multicenter Retrospective Study. *Blood Purif.* 2016;42(2):93–9.
19. Hsu CW, Lin JL, Lin-Tan DT, et al. Early hemoperfusion may improve survival of severely paraquat-poisoned patients. *PLoS One.* 2012;7(10):e48397.
20. Nasr Isfahani S, Farajzadegan Z, Sabzghabae AM, et al. Does hemoperfusion in combination with other treatments reduce the mortality of patients with paraquat poisoning more than hemoperfusion alone: A systematic review with meta-analysis. *J Res Med Sci.* 2019 Jan 31;24:2.
21. Pond SM, Rivory LP, Hampson EC, et al. Kinetics of toxic doses of paraquat and the effects of haemoperfusion in the dog. *J Toxicol Clin Toxicol.* 1993;31:229–46.
22. Hong SY, Yang JO, Lee EY, et al. Effect of haemoperfusion on plasma paraquat concentration in vitro and in vivo. *Toxicol Ind Health* 2003;19:17.
23. Jin K, Guo L, Shao M, et al. [Intensity of hemoperfusion in acute paraquat-poisoned patients and analysis of prognosis]. *Zhonghua Wei Zhong Bing Ji Jiu Yi Xue.* 2015 Apr;27(4):263-9.
24. Zhao X, Xiao Y, Zhu J, et al. Prognostic comparison of goal-oriented hemoperfusion and routine hemoperfusion combined with continuous venovenous hemofiltration for paraquat poisoning. *J Int Med Res.* 2018 Mar;46(3):1091-1102.
25. Sun Y, Fan Z, Zheng T, et al. [Efficacy of hemoperfusion combined with continuous veno-venous hemofiltration on the treatment of paraquat poisoning: a Meta-analysis]. *Zhonghua Wei Zhong Bing Ji Jiu Yi Xue.* 2020 Jun;32(6):726–31.
26. Eizadi-Mood N, Jaber D, Barouti Z, et al. The efficacy of hemodialysis on paraquat poisoning mortality: A systematic review and meta-analysis. *J Res Med Sci.* 2022 Sep 27;27:74.
27. Lin G, Long J, Luo Y, et al. Continuous venovenous hemofiltration in the management of paraquat poisoning: A meta-analysis of randomized controlled trials. *Medicine (Baltimore).* 2017 May;96(20):e6875.
28. AU Yeh ST, Guo HR, Su YS, et al. Protective effects of N-acetylcysteine treatment post acute paraquat intoxication in rats and in human lung epithelial cells. *Toxicology.* 2006;223(3):181. Epub 2006 Apr 6.
29. Mehalingam Vadivelan, Anand Chellappan, B. S. Suryanarayana. The ‘Golden Hour’ in Paraquat Poisoning. *Toxicol Int.* 2014 Sep-Dec;21(3):339–40.
30. AU Wu WP, Lai MN, Lin CH, et al. Addition of immunosuppressive treatment to hemoperfusion is associated with improved survival after paraquat poisoning: a nationwide study. *PLoS One.* 2014;9(1):e87568. Epub 2014 Jan 27.
31. Delirrad M, Majidi M, Boushehri B. Clinical features and prognosis of paraquat poisoning: a review of 41 cases. *Int. J. Clin. Exp. Med.* 2015;8:8122–8.
32. Sabzghabae AM, Eizadi-Mood N, Montazeri K, et al. Fatality in paraquat poisoning. *Singapore Med J* 2010;51:496–500.

33. Yokoyama T, Kondoh Y, Taniguchi H, et al. Noninvasive ventilation in acute exacerbation of idiopathic pulmonary fibrosis. *Intern Med.* 2010;49(15):1509-1514. doi:10.2169/internalmedicine.49.3222.
34. Seifirad S, Keshavarz A, Taslimi S, et al. Effect of pirfenidone on pulmonary fibrosis due to paraquat poisoning in rats. *Clin Toxicol (Phila).* 2012;50(8):754–8. doi:10.3109/15563650.2012.718783
35. Sanaei-Zadeh H. Can pirfenidone prevent paraquat-induced pulmonary injury? a hypothesis. *Tzu. Chi. Med. J.* 2012;4:223. doi: 10.1016/j.tcmj.2012.07.001.
36. Tang X, Sun B, He H, et al. Successful extracorporeal membrane oxygenation therapy as a bridge to sequential bilateral lung transplantation for a patient after severe paraquat poisoning. *Clin Toxicol (Phila).* 2015;53(9):908–13. doi:10.3109/15563650.2015.1082183
37. Bertram, A., Haenel, S.S., Hadem, J. et al. Tissue concentration of paraquat on day 32 after intoxication and failed bridge to transplantation by extracorporeal membrane oxygenation therapy. *BMC Pharmacol Toxicol* 14, 45 (2013). <https://doi.org/10.1186/2050-6511-14-45>
38. Jiao G, Li X, Wu B, et al. Case Report: Delayed Lung Transplantation With Intraoperative ECMO Support for Herbicide Intoxication-Related Irreversible Pulmonary Fibrosis: Strategy and Outcome. *Front Surg.* 2021;8:754816. Published 2021 Nov 26. doi:10.3389/fsurg.2021.754816.