

Textbook of Forensic Histopathology

is a foundation book aimed at all the postgraduate students and young practitioners of forensic medicine and toxicology. The book attempts to develop and bring in a culture of quality forensic services and bridge the gap in the current postgraduate forensic training in the subcontinent where histopathology is either not taught properly or taught superficially to forensic pathology practitioners.

Salient Features

- The text covers basic issues to advance knowledge in histopathology in 42 chapters.
- The book covers the subject from basics of histology and anatomical pathology to forensic pathology so as to make the student understand the complexities better and in a simplified form.
- All forensic chapters have relevant case illustrations.
- All the chapters deal with the common issues faced by most forensic practitioners.
- There are ideal postmortem reports supplemented with multicolour gross and histopathological pictures.
- A colour atlas is given for quick assessment of key findings.
- In times to come, it would serve as a permanent companion to all the postgraduate students as well as the teachers of forensic medicine and toxicology.

OP Murty MD

is currently Professor, Department of Forensic Medicine and Toxicology, All India Institute of Medical Sciences (AIIMS), New Delhi. He is an eminent teacher with more than three decades of experience of teaching FMT at prestigious institutions in India and abroad. He completed his graduation and postgraduation from Maulana Azad Medical College (MAMC), New Delhi. He served as senior demonstrator at MAMC and then shifted to AIIMS as a regular faculty in 1992. He has also been Professor of Forensic Pathology at UiTM, Malaysia, and King Faisal University, Dammam, Kingdom of Saudi Arabia; and Associate Professor and Unit Head of Forensic Pathology, University of Malaysia, Kuala Lumpur, Malaysia, where histopathology was an integral part of forensic pathology cases.



Prof Murty has to his credit more than 150 scientific papers published in national and international journals. He has authored a manual for UNICEF and three other books *Operational Guidelines in Medical Toxicology*, *Essentials of Forensic Medicine and Toxicology* and *Operational Guidelines for Postmortem Examinations and Auditing*. He is coauthor of a popular textbook *Essentials of Forensic Medicine and Toxicology*, 35/e by KS Narayan Reddy. He has been editor-in-chief of *Journal of Forensic Medicine and Toxicology* (ISSN 0971-1929) and *International Journal of Medical Toxicology and Legal Medicine* (ISSN 0972-0448) and is on the editorial boards of many national and international journals. He has been elected twice as General Secretary, Indian Academy of Forensic Medicine (2000-2004). He has been appointed as national guest faculty by National Institute of Criminology and Forensic Science (NICFS).



CBS Publishers & Distributors Pvt Ltd
4819/XI, Prahlad Street, 24 Ansari Road, Daryaganj, New Delhi 110 002, India
E-mail: delhi@cbspd.com, cbspubs@airtelmail.in; Website: www.cbspd.com
New Delhi | Bengaluru | Chennai | Kochi | Kolkata | Lucknow | Mumbai
Hyderabad | Jharkhand | Nagpur | Patna | Pune | Uttarakhand



ISBN: 978-93-5466-003-0

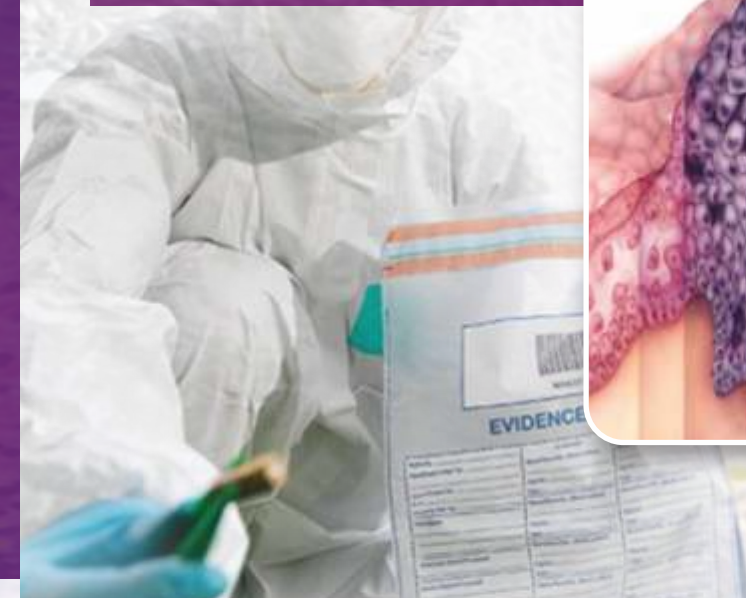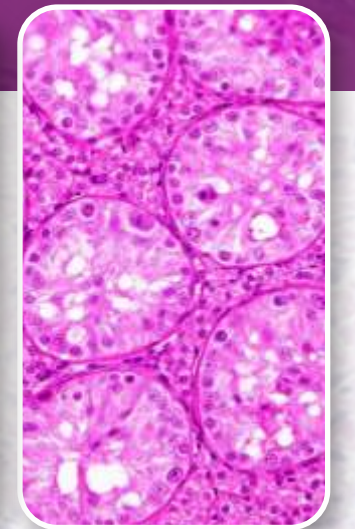
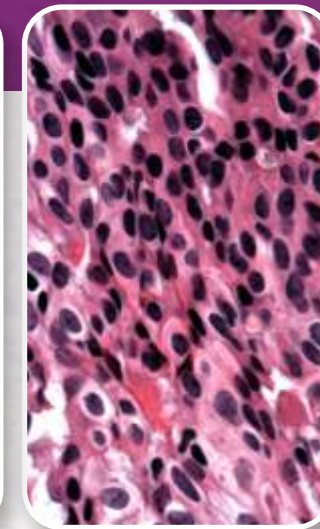


Murty



Textbook of
Forensic Histopathology

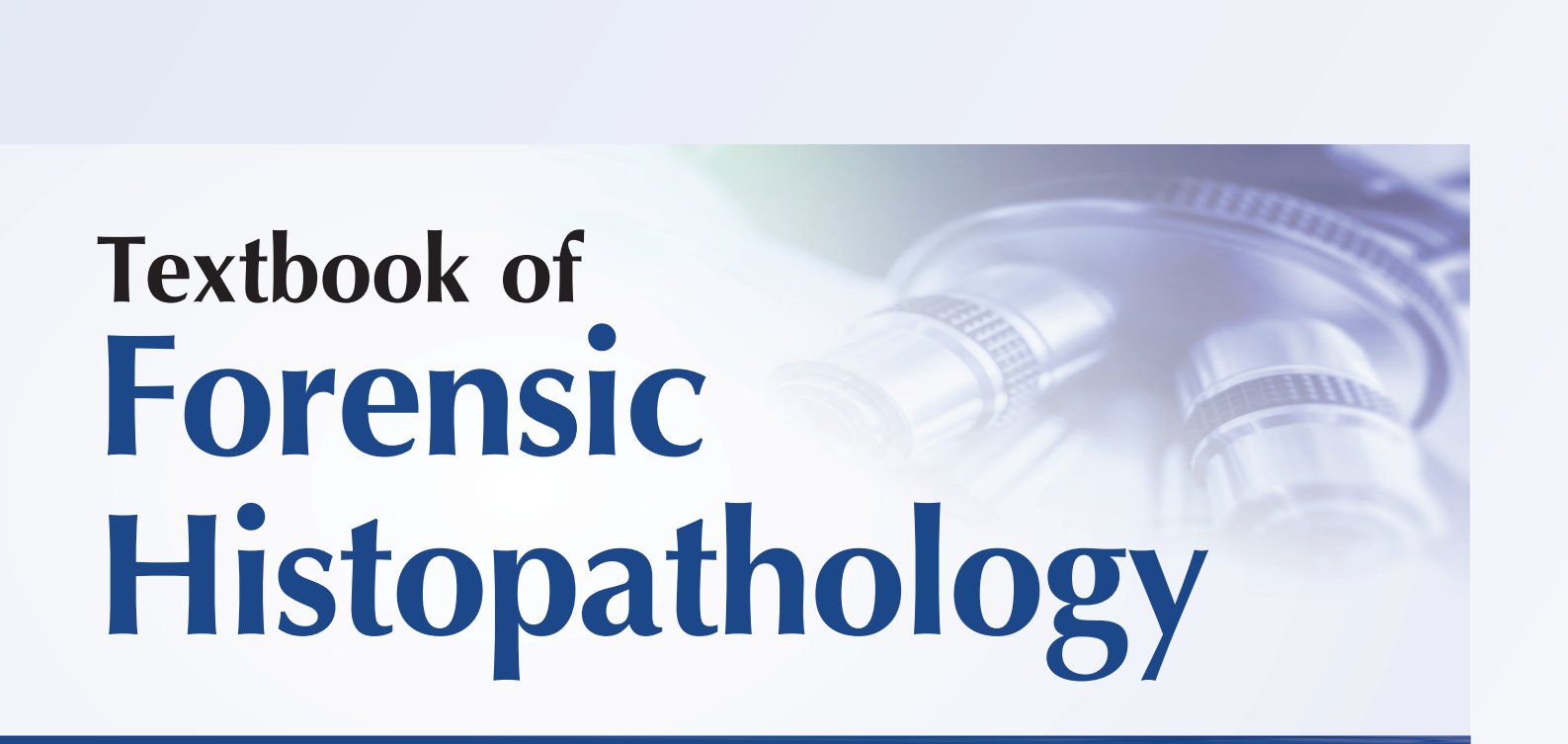
Textbook of Forensic Histopathology



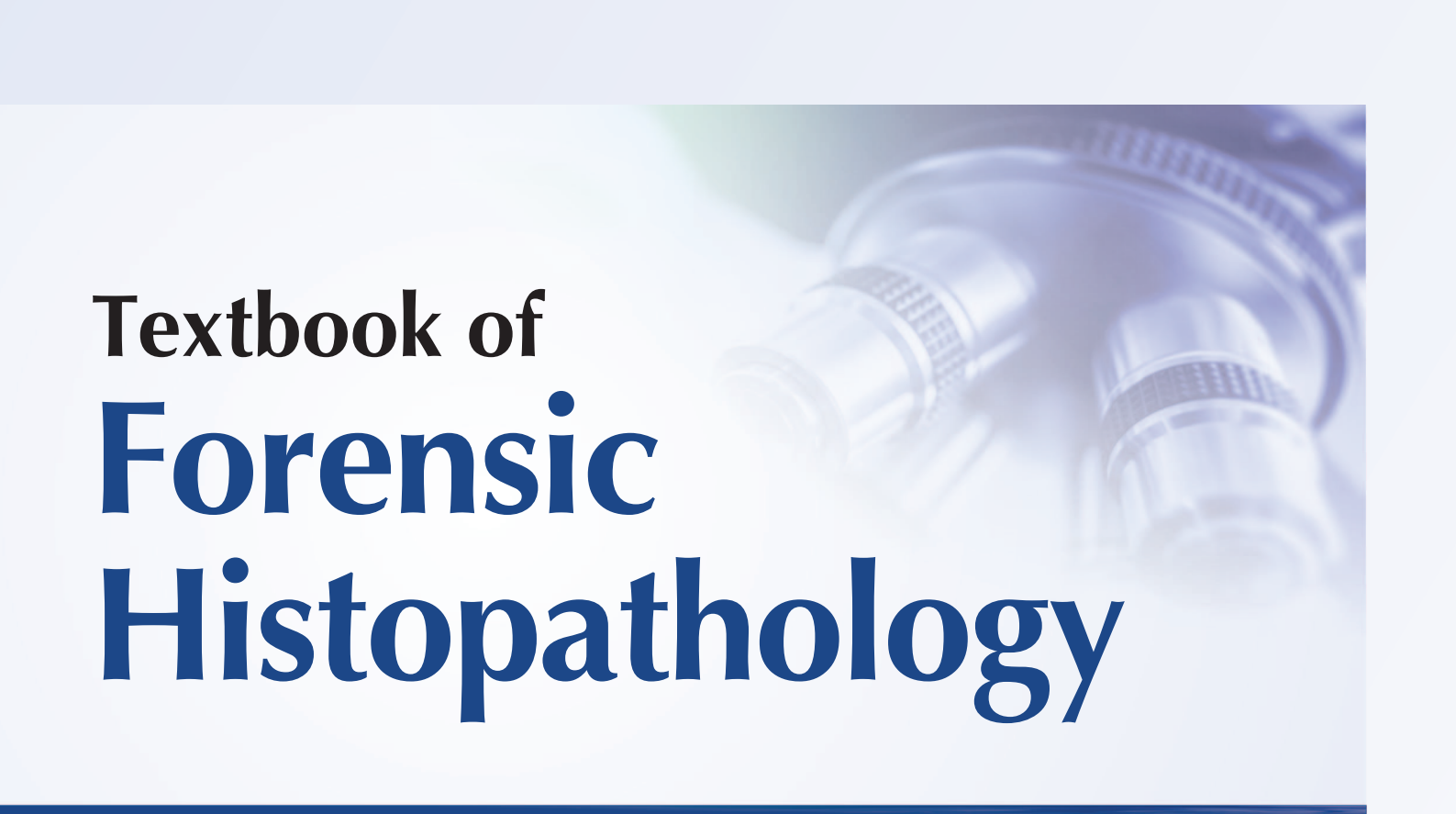
OP Murty



CBSPD Dedicated to Education
CBS Publishers & Distributors Pvt Ltd

A close-up, slightly blurred image of a microscope's objective lenses and eyepiece, set against a light blue background. The image is positioned in the upper right corner of the page.

Textbook of
Forensic
Histopathology



Textbook of Forensic Histopathology

OP Murty

MBBS MD

Professor

Department of Forensic Medicine and Toxicology
All India Institute of Medical Sciences
New Delhi, India

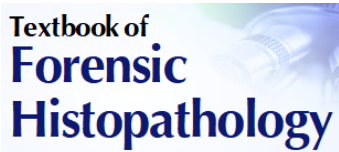


CBS Publishers & Distributors Pvt Ltd

Delhi • Bengaluru • Chennai • Kochi • Kolkata • Lucknow • Mumbai
Hyderabad • Jharkhand • Nagpur • Patna • Pune • Uttarakhand

Disclaimer

Science and technology are constantly changing fields. New research and experience broaden the scope of information and knowledge. The author has tried his best in giving information available to him while preparing the material for this book. Although all efforts have been made to ensure optimum accuracy of the material, yet it is quite possible some errors might have been left uncorrected. The publisher, the printer and the author will not be held responsible for any inadvertent errors or inaccuracies.



Textbook of Forensic Histopathology

ISBN: 978-93-5466-003-0

Copyright © Author and Publisher

First Edition: 2022

All rights reserved. No part of this book may be reproduced or transmitted in any form or by any means, electronic or mechanical, including photocopying, recording, or any information storage and retrieval system without the prior permission in written from the author and the publisher.

Published by **Satish Kumar Jain** and produced by Varun Jain for

CBS Publishers & Distributors Pvt Ltd

4819/XI Prahlad Street, 24 Ansari Road, Daryaganj, New Delhi 110 002, India

Ph: 011-23289259, 23266861, 23266867 Fax: 011-23243014

Website: www.cbspd.com

e-mail: delhi@cbspd.com; cbspubs@airtelmail.in

Corporate Office: 204 FIE, Industrial Area, Patparganj, Delhi 110 092

Ph: 011-4934 4934

Fax: 011-4934 4935

e-mail: publishing@cbspd.com; publicity@cbspd.com

Branches

- **Bengaluru:** Seema House 2975, 17th Cross, KR Road, Banasankari 2nd Stage, Bengaluru 560 070, Karnataka, India
Ph: +91-80-26771678/79 Fax: +91-80-26771680 e-mail: bangalore@cbspd.com
- **Chennai:** 7, Subbaraya Street, Shenoy Nagar, Chennai 600 030, Tamil Nadu, India
Ph: +91-44-26680620, 26681266 Fax: +91-44-42032115 e-mail: chennai@cbspd.com
- **Kochi:** 42/1325, 1326, Power House Road, Opp KSEB Power House, Ernakulam 682 018, Kochi, Kerala, India
Ph: +91-484-4059061-65 Fax: +91-484-4059065 e-mail: kochi@cbspd.com
- **Kolkata:** 147, Hind Ceramics Compound, 1st Floor, Nilgunj Road, Belghoria, Kolkata 700 056, West Bengal, India
Ph: +91-33-25633055/56 e-mail: kolkata@cbspd.com
- **Lucknow:** Basement, Khushnuma Complex, 7-Meerabai Marg (behind Jawahar Bhawan), Lucknow 226 001, UP, India
Ph: +91-522-4000032 e-mail: tiwari.lucknow@cbspd.com
- **Mumbai:** PWD Shed, Gala No. 25/26, Ramchandra Bhatt Marg, Next to JJ Hospital Gate No. 2, Opp. Union Bank of India, Noorbaug, Mumbai 400 009, Maharashtra, India
Ph: +91-22-66661880/89 e-mail: mumbai@cbspd.com

Representatives

- | | | | | | |
|--------------------|--------------|--------------------|--------------|----------------------|--------------|
| • Hyderabad | 0-9885175004 | • Jharkhand | 0-9811541605 | • Nagpur | 0-9421945513 |
| • Patna | 0-9334159340 | • Pune | 0-9623451994 | • Uttarakhand | 0-9716462459 |

Printed at: Rahul Print 'O' Pack Press, Delhi, India

Preface

This is a basic foundation book and is not a replacement to standard pathology books. The guidance of a qualified pathologist is always helpful in difficult cases. If histopathology is being practiced by forensic practitioners then they can resolve a majority of cases. In fact, this is a kind of modular teaching at postgraduate level.

Histopathology is a very important investigation in deciding sudden natural death, time of injury and specific findings in certain cases. In the assessment of medical findings, in the administration of justice, a particularly high degree of reliability of the evidence has to be obtained. In forensic practice nothing is so trivial and small that it cannot become the decisive factor in the outcome of the case.

A hasty curtailment of the histological investigation is frequently a relinquishment of knowledge and evidential possibilities which cannot later be recovered. Today, in majority of cases, the cause of death is still being concluded without the use of histology, the reasons are diverse: (i) Specialized knowledge and understanding of the necessity of a histological examination are absent, (ii) investigating officers and doctors conducting postmortem examination are interested in the 'quick settlement' of a case, (iii) an enquiry into a case appears 'sufficiently clear' from macroscopic findings alone, (iv) there is no orientation of such examination among experts due to insufficient training.

An experienced medical man knows the necessity of further examination and the extent to which histological examination can be helpful over the naked eye examination. In many parts of the world, it is considered as a lapse if macroscopic findings are not being supplemented by histological findings. This simplified approach in the form of **Textbook of Forensic Histopathology** will be helpful in:

1. Study of histopathology of natural diseases and some histological aspects of forensic cases.
2. Study of morbid anatomy and pathological changes in organs during postmortem examinations and follow-up of these cases in histopathology laboratory.
3. Interpretation of findings in relation to medicolegal issues.
4. Report writing through examples of case scenarios.
5. Opinion expression in relation to different medicolegal situations.

This idea was conceived during my formative years and we organized an international conference on forensic histopathology and cytology in 1998. The working in Malaysia enriched my experience in this subject. At University of Malaya, Kuala Lumpur, forensic histopathology was a part of pathology department. Here, medicolegal and clinical autopsies were conducted by forensic people. This opportunity greatly enriched my experience in this art.

This book is well organized into 42 chapters which cover subjects from basics of histology to advances in forensic pathology albeit in simplified form. All chapters have case illustrations. Any suggestion to improve this modest and humble venture will be appreciated.

OP Murty

Acknowledgements

This book manifests synergistic input of a team of young and senior professionals whom I wish to acknowledge here. It is my great pleasure to acknowledge the help extended by Prof AK Mandal (VMC and Director ANIMS), Prof KT Wong (UM), Dr Mohd Shah (HKL), Prof Usha Sabharwal (AIIMS), Prof Shashi Wadhwa (AIIMS), Prof (Dr) Anil Kohli, Prof SK Verma, Prof NK Aggarwal, Prof KK Banerjee (UCMS), Prof SK Sharma (AFMC, Delhi), Prof Shiv Rattan Kochar (Jaipur), Prof Anil Kumar Mittal (MAMC), Prof Arun Agnihotri and Prof Smiriti Agnihotri (Maritius), Prof G Sunil Kumar Sharma (VMC), Prof Rajendra Bangal (MS), Prof CB Jani (Ahmadabad), Prof BH Tirpude (Wardha), Late Prof RS Naik (Wardha), Dr Anand Verma (ESI, Delhi), Dr Asit Kumar Sikary (Bareilly, UP), Dr Sone Lal (Forensic Specialist) and Prof Sarman Singh (Microbiology, AIIMS).

Our young colleagues mainly senior residents are very useful in analyzing utility of any document as they are users of such document. I am indebted to our senior residents who critically analyzed the scripts and contents. I express my gratitude to my resident colleagues who helped in the proofreading, especially Dr Pooja Gajmer, Dr Abdul Raoof Madathi Para, Dr Venketesh Janarthanam, Dr Karthi Vignesh Raj, Dr Swati Tyagi, senior residents FMT AIIMS, New Delhi.

My sincere thanks to Prof Anshoo Agarwal (MBBS), Northern Borders University, Kingdom of Saudi Arabia for her constant advise on difficult microscopic slides. I sincerely appreciate role of Dr Aravindan V and Dr Benji Tom Varughese for helping in final editorial work.

I sincerely appreciate the photograph contribution of Prof Manoj Kumar Pathak, Dr Rohini Diwakar (BHU and AIIMS, Patna) for electron microscopic picture of heart, Dr Maksim Aleksanrovich Kislov (Moscow), Dr Mohit Chauhan (GMC, Chandigarh) and their team for Covid lesions gross and microscopic photographs. I appreciate Prof A Shariff (Anatomy) and his senior resident Dr Kishor for permitting their microscopic camera for taking few microphotographs. My sincere appreciation and thanks to Mr Daya Shankar and Ms Reema Bagga for initial formatting of this book.

My highest regards to my mentor Late Prof K S Narayan Reddy who was a constant guide in my academic life. My sincere thanks to all those who helped me in various ways in this journey, especially my faculty and resident colleagues with whom I had an opportunity to work. I had good teaching and training under learned teachers Prof Bishnu Kumar, Dr George Paul and Dr Anil Aggarwal.

Producing a textbook with so many color photographs and diagrams is truly a team effort between author and publisher. I am grateful to CEO Mr Satish Jain and Vice-President Mr YN Arjuna of CBS Publishers & Distributors Pvt Ltd, New Delhi, for publishing this book.

With gratitude

OP Murty

Contents

<i>Preface</i>	v	
1. Forensic Histopathology	1	
Introduction	1	
Objectives	1	
Important Lesions in Forensic Practice	1	
2. Histology of Forensic Interest	4	
Skin	4	
Cardiovascular System	4	
Respiratory System	5	
Central Nervous System	5	
Gastrointestinal Tract	5	
Female Reproductive System	6	
Placenta	7	
Umbilical Cord	7	
3. General Pathology of Forensic Interest	8	
Introduction	8	
Pathogenesis	8	
Hypertrophy	9	
Hyperplasia	9	
Metaplasia	9	
Developmental Decrease in Growth	9	
Aplasia	9	
Cell Injury	10	
Mucoid Degeneration	10	
Hyaline Degeneration	10	
Apoptosis	11	
Necrosis	11	
Gangrene	11	
Infarction	12	
Inflammation	12	
Thrombus	15	
Embolism	15	
Shock	15	
4. Microbiology in Autopsy	16	
Introduction	16	
Laboratory Procedures	16	
Sampling in Autopsy Cases	17	
Identification	18	
5. Grossing and Tissue Processing	20	
Introduction	20	
Sampling and Grossing	20	
Fixation	22	
Dehydration	22	
Clearing	23	
Embedding	23	
Block Making	23	
Sectioning	23	
Mounting	23	
Hydration	23	
Staining	23	
Reporting	23	
Record Keeping	23	
Court Presentation	23	
Disposal of Waste	24	
Causes of Improper Sectioning	24	
Artefacts	24	
Glossary of Terms for Shape	24	
Glossary of Margins	25	
Glossary of Color	25	
Glossary for Consistency	25	
6. Organ Tissue Blocks	27	
Introduction	27	
Tissue Blocks	27	
Routine Blocks in Adults	28	
College of American Pathologists	28	
7. Decomposition	30	
Introduction	30	
Autolysis	30	
Putrefaction	30	
Histology in Putrefaction	30	
Blood	31	
Liver	32	
Kidneys	32	
Heart	32	
Lungs	33	
Central Nervous System (CNS)	33	
Esophagus	33	
Larynx and Trachea	33	
Gallbladder	33	
Omentum and Mesentery	33	
Pituitary Gland	33	
Pancreas	33	
Spleen	34	
Small Intestine	34	
Epididymis	34	

Bladder 34	Testes 58
Uterus 34	Spleen 58
Prostate 34	Lungs 58
Adrenals 34	Kidneys 59
Bones 34	Prostate 59
Skeletal Tissues 34	Pancreas 62
Hair 34	Choroid Plexus in Brain 62
Adipocere 34	
Exhumed Corpses 35	
Glycophorin A 35	
Time of Death 35	
8. Time Since Death 42	
Introduction 42	
Heart 42	
Kidney 42	
Uterus 42	
Vaginal Smears 43	
Epididymis 44	
Alcoholic Graph 44	
Food Contents in GIT 44	
Maggots Appearance 44	
Other Postmortem Changes 44	
9. Injury Dating 46	
Introduction 46	
Reading in Injury 46	
Healing and Repair 47	
Wound Healing 47	
Open Wound Healing 47	
Bruise 48	
Abrasion 48	
Incised Wound Declinng 49	
Bone Fracture Callus Formation 49	
Burn Injury 49	
Brain: Cortical Contusion 50	
Neurons Changes 50	
Subdural Hematoma (SDH) 51	
Brain Fixation 52	
Pulmonary Pathology 52	
Duration of Clot 53	
Thrombus Duration 53	
10. Age from Organ Histology 55	
Introduction 55	
Heart 55	
Conduction System 56	
Coronary Arteries 56	
Uterus 56	
Breast 57	
Ovary 57	
11. Age from Bone Osteology 64	
Bone Osteology 64	
Bone Matrix 64	
Age Determination 64	
12. Developing and Ageing Brain 68	
Introduction 68	
Development of Cerebral Cortex 68	
Cortical Architecture 69	
Myelination 69	
Ventricular System 69	
Cerebellum 69	
Ageing 60	
Forensic View 70	
13. Scalds and Burns 71	
Scalds 71	
Burns 71	
Skin 71	
Skin Histology 73	
Organ Pathology in Burns 73	
Respiratory Tract 73	
Kidneys 74	
Gastrointestinal Tract 74	
Spleen 74	
Adrenals 74	
Brain 75	
Heart 75	
Antemortem or Postmortem Burns 75	
Fat Embolism 76	
Burn Wound Infection 76	
Identification of Burnt Remains 77	
14. Mechanical Asphyxia 96	
Asphyxia 96	
Hypoxic and Ischemic Brain Damage 96	
Spectrum of Asphyxial Deaths 97	
Mechanism of Death 98	
Classical Signs of Asphyxia 98	
Pitfalls of Clinical Signs 98	
Role of Histopathological Examination 98	
Stains Useful in Asphyxia 99	
Histopathological Changes in the Neck 99	

Changes in Internal Organs 99		Acute Hemorrhagic Pancreatitis 198	
Hanging 99		Cirrhosis of Liver 199	
Strangulation 103		Hepatic Failure 204	
Gagging 106		Malignant Lesions 207	
Bag Suffocation 107		Liver Cancer 208	
Traumatic Asphyxia 108		Adenocarcinoma of Stomach 210	
Asphyxia due to Blood Aspiration 110		Adenocarcinoma of Colon 210	
Suffocation due to Exhaust Fumes 111			
15. Cardiovascular System	112	18. Central Nervous System	213
Heart: Normal Anatomy 112		Introduction 213	
Blood Supply of Heart 114		Normal Anatomy of Brain 213	
Sudden Cardiac Deaths 117		Dissection of Brain 214	
Important Cardiac Lesions 121		Special Stains 214	
Atherosclerosis 122		Infections 215	
Coronary Thrombosis 125		Opportunistic Infections 217	
Aneurysm Rupture 129		CNS Tumors 219	
Dilated Cardiomyopathy 134		Common Lesions 219	
Hypertrophic Cardiomyopathy 136		Intracranial Hemorrhages 220	
Myocarditis 138		Epilepsy 225	
Giant Cell Myocarditis 143		Cysticercosis 225	
Chronic Myocarditis and Pericarditis 144			
Hypertension 146		19. Endocrine System	228
Conduction System 151		Introduction 228	
Cardiac Tamponade 154		Pituitary Infarction 228	
		Diabetic Disease 228	
16. Respiratory System	157	Seminoma of Testes 235	
Introduction 157		Thyroid Disorders 239	
Acute Lung Injury (ALI)/Acute Respiratory Distress Syndrome (ARDS) 157		Adrenal Insufficiency 239	
Pneumonia 157			
Viral Pneumonia 159		20. Obstetrics and Gynecology (OBG)	246
Pulmonary Thromboembolism 161		Introduction 246	
Tuberculosis 171		Basics of OBG Physiology and Histology 246	
Bronchial Asthma 175		Maternal Deaths 248	
Obstructive Lung Diseases 180		Ectopic Pregnancy 259	
Emphysema 180		Autopsy in Maternal Deaths 265	
Pleural Effusion 181		Medical Negligence Issues in OBG 268	
Hemothorax 181			
Pneumothorax 182		21. Drug and Substance Abuse	270
Air Embolism 183		Definition 270	
Tumor Emboli 183		Medical Examination 270	
		Histopathological Aspect of Addiction 271	
17. Gastrointestinal System	185	Cocaine Addiction 272	
Introduction 185		Heroin Abuse 272	
Acute Gastroenteritis 185		Morphine Addiction 273	
Gastritis 187		Substance Abuse 274	
Esophageal Varices 188			
Perforations of Ulcers 189		22. HIV and Related Infections	275
Peritonitis 192		HIV 275	
Acute Intestinal Obstruction 194		Types of Opportunistic Infections 275	
Ischemic Disease of Intestine 196		Cerebral Toxoplasmosis 276	
		Cryptococcosis 277	
		Candidiasis 277	

23. Sexual Offences	284	Tuberculosis 329	
Anatomy and Histology 284		Radiation Effects 329	
Sexual Offences 285		29. Vector-borne Diseases	331
Findings in Sexual Contact 286		Dengue 331	
Fate of Semen in Human Vagina 286		Malaria 332	
Vaginal Smear Examination in Forensic Practice 286		30. Sex Determination by Chromatin	335
Different Swabs 287		Introduction 335	
Microscopic Examination 288		Importance of Sex Determination 335	
Detection of Spermatozoa in Relation to Postmortem Interval 289		Specimens 336	
Condom Lubricant 290		Fixation 336	
Findings in Sodomy 290		Staining Materials 336	
STD (Venereal or Sexually Transmitted Disease and Rape) 291		Quinacrine Dihydrochloride 336	
24. Stillbirth and Newborn	297	Citric Acid Phosphate Buffer (pH 5.5) 336	
Stillbirth 297		Phosphate Buffer (pH 7.4) 337	
25. Sudden Infant Death Syndrome	316	Fluorescent Schiff Type Reagent 337	
Introduction 316		Fluorescent Microscope 337	
Major Diseases 316		Fluorescent Staining Procedure for 'Y' and 'X' 337	
Death in Bed 316		Demonstration 337	
Different Systems 316		31. Coronavirus Disease (Covid-19)	338
26. Lightning	318	Introduction 338	
Introduction 318		Investigations 339	
Central Nervous System (CNS) 321		Autopsy 339	
Cardiovascular System (CVS) 321		32. Forensic Entomology	343
Respiratory Damage 322		Introduction 343	
Gastrointestinal Tract (GIT) 322		Background Information 343	
Skin 322		Scene Management 345	
27. Electrocutation	324	Influencing Factors 347	
Introduction 324		Fly and Beetles Biology on Corpses 347	
Skin: Basic Histology 324		Method of Description 348	
Postmortem Findings 325		Postmortem Interval 348	
Microscopic Findings 325		Case Workout 353	
28. Occupational Diseases	327	33. Poisoning	354
Introduction 327		Introduction 354	
Silicosis 327		General Findings in Poisoning 354	
Anthraxosis 328		Viscera for Chemical Analysis 356	
Asbestosis 328		Pesticides 357	
Beryllium Pneumonitis 328		Hydrocarbons 357	
Bauxite Fibrosis 328		Organophosphorous Poisoning 358	
Graphite Fibrosis 328		Paraquat Poisoning 360	
Byssinosis 329		Grains Fumigants 364	
NO ₂ Fumes 329		Aspirin Diosyncrasy (Reye Syndrome) 366	
Farmer's Lung 329		Drug Abuse and Medicine Overdose 368	
		Alcohol Intoxication 373	
		Sea Creatures' Poisoning 381	

- Insect and Snake Bites 381
 Asphyxiant 388
 Hydrogen Sulphide (Sewage Gas) 392
 Corrosives 393
 Food Substances (Cyanogenic Foods) 396
 Poisonous Plants 396
 Epidemic Dropsy 401
- 34. Diseases and Bio-safety at Forensic Workplace 406**
- Introduction 406
 Diseases 406
 Injuries at Workplace 406
 Incidental Infections 406
 Self-suffered Infections 407
 Toxicity 407
 Mental Illness 407
 Prevention 407
 Personal Protective Equipments 407
 Aerosolized Pathogens 407
 Waste Management 408
 Transport of Specimens 408
 Decontamination 408
 First Aid 408
 Immunization and Medical Surveillance 408
- 35. Lesions of Forensic Interest 410**
- Anaphylactic Reactions 410
 Mismatched Blood Transfusion 411
 Heart 411
 Lungs 415
 Liver 417
 Brain 418
 Kidneys 419
 Age of Clot 420
 Burns 420
 Epilepsy 420
 Buccal Cytology 421
 Placenta 421
 Electric Current Injury (Electrocution) 421
 Slides for Mismatched Blood Transfusion 421
- 36. Quick Diagnosis-I: Synopsis of Basic Lesions 426**
- Cardiovascular System 426
 Myocardial Ischemia 427
 Respiratory System 430
 Gastrointestinal Tract 432
 Liver 434
 Kidneys 435
- Pancreas 436
 Obstetric Conditions 436
 Adrenal Glands 437
 Trauma 437
 Miscellaneous 437
- 37. Quick Diagnosis-II: Micrographs 439**
- Cardiovascular System 439
 Respiratory System 457
 Central Nervous System 468
 Brain 472
 Kidneys 472
 Adrenal Gland 478
 Liver 479
 Skin 487
 Obstetrics and Gynaecology 489
 Sexual Assault 491
 Miscellaneous 495
 Hairs 499
 Aluminum Phosphide 501
- 38. Microscope 505**
- Introduction 505
 Types of Microscopes 505
 Parts of Compound Microscope 505
 Magnification 506
 Use of Microscope 507
 Setting up a Microscope 507
 Care of Microscope 507
 Ultraviolet or Fluorescent Microscopy 508
 Polarizing Microscopy 508
- 39. Electron Microscopy in Forensics 509**
- Introduction 509
 Examination of Trace Evidences 509
 Transmission Electron Microscopy (TEM) 510
 Major Components of TEM 510
 Scanning Electron Microscopy (SEM) 510
 Application of SEM 510
 SEM-EDX 511
- 40. Staining Methods 512**
- Introduction 512
 Hematoxylin and Eosin (H&E) Staining 512
 Sexual Assault Cases 513
 Sex Chromatin 514
 Fibrin 515
 Amniotic Fluid Embolism 515
 Myocardium 515
 Special Stains 517
 Microorganisms and Appropriate Stains 518

41. Forensic Museum	519	42. Radiation	527
Introduction	519	Introduction	527
Objectives	519	Measurement of Radiation Doses	527
Organization	519	Types of Exposure on Human Body	527
Types of Museum	520	Radiation Doses and their Effects	528
Documentation and Catalogue	522	Symptoms and Signs of Radiation Exposure	528
Fixation of Specimens	522	Histopathology Findings in Radiation Exposure	528
Ethical and Legal Aspect	524	Causes of Death	528
Disposal of Biomedical Waste	525	Special Instructions	529
Futuristic Approach: A Way Forward in Museum Building	525	Heat Radiation	529
		Index	531