

# Concise Oral Radiology

Third  
Edition

Third  
Edition

Third  
Edition

Concise  
Oral  
Radiology

# Concise Oral Radiology

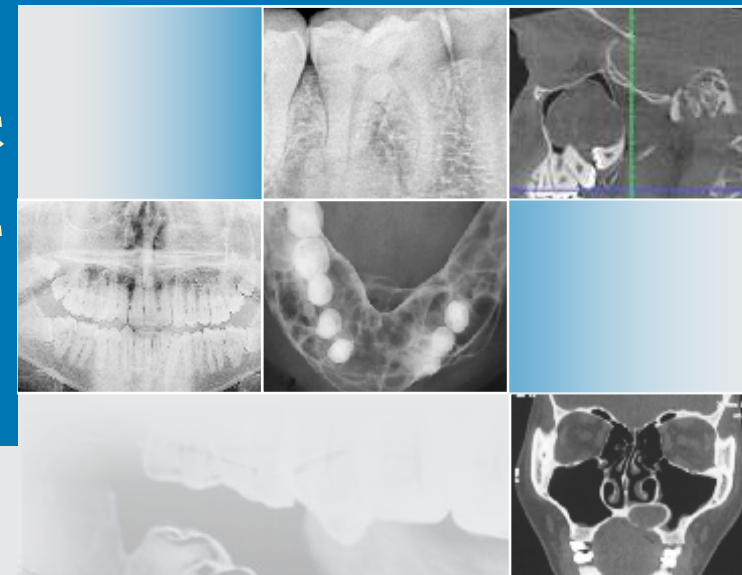
is the thoroughly revised and updated edition of the book which also includes recent information on the basic and advanced aspects of the subject. Like the previous editions, this edition of the textbook presents the subject in a concise, easily understandable and student-friendly manner.

This edition features new, interesting and representative radiographs, illustrations and images, which have been added to elucidate the radiographic interpretation. The additional information in the advanced imaging modalities will contribute towards better understanding of CBCT, CT, MRI, etc.

The book aims to help the students understand, enjoy and master all the topics so that they can **Read, Remember, Recall and Reproduce** the subject not only during the examinations but also in the clinical practice.

**HR Umarji** MDS (Oral Medicine and Radiology)

is ex-Professor and Head, Department of Oral Medicine and Radiology, Government Dental College and Hospital, Mumbai. He is a dedicated and experienced teacher in the field of oral medicine and radiology. He is author of another CBS title *Concise Oral Medicine*.



**HR Umarji**



**CBS Publishers & Distributors Pvt Ltd**  
4819/XI, Prahlad Street, 24 Ansari Road, Daryaganj, New Delhi 110 002, India  
E-mail: delhi@cbspd.com, cbspubs@airtelmail.in, Website: www.cbspd.com  
New Delhi | Bengaluru | Chennai | Kochi | Kolkata | Lucknow | Mumbai  
Hyderabad | Jharkhand | Nagpur | Patna | Pune | Uttarakhand



**CBS Publishers & Distributors Pvt Ltd**

Third Edition

Concise

**Oral**

**Radiology**



Third Edition

# Concise Oral Radiology

**HR Umarji**


MDS (Oral Medicine and Radiology)

*Former Professor and Head*  
Department of Oral Medicine and Radiology  
Government Dental College and Hospital  
Mumbai



**CBS Publishers & Distributors Pvt Ltd**

New Delhi • Bengaluru • Chennai • Kochi • Kolkata • Lucknow • Mumbai  
Hyderabad • Jharkhand • Nagpur • Patna • Pune • Uttarakhand



ISBN: 978-93-5466-052-8

Copyright © author and publisher

### Third Edition: 2022

*Second Edition:* 2011

*Reprint:* 2015, 2017

*First Edition:* 2008

All rights are reserved. No part of this book may be reproduced or transmitted in any form or by any means, electronic or mechanical, including photocopying, recording, or any information storage and retrieval system without permission, in writing, from the author and the publisher.

Published by [Satish Kumar Jain](#) and produced by [Varun Jain](#) for

#### CBS Publishers & Distributors Pvt Ltd

4819/XI Prahlad Street, 24 Ansari Road, Daryaganj, New Delhi 110 002, India

Ph: 011-23289259, 23266861, 23266867 Fax: 011-23243014

Website: [www.cbspd.com](http://www.cbspd.com)  
e-mail: [delhi@cbspd.com](mailto:delhi@cbspd.com);  
[cbspubs@airtelmail.in](mailto:cbspubs@airtelmail.in).

*Corporate Office:* 204 FIE, Industrial Area, Patparganj, Delhi 110 092, India

Ph: 011-4934 4934

Fax: 011-4934 4935

e-mail: [publishing@cbspd.com](mailto:publishing@cbspd.com);  
[publicity@cbspd.com](mailto:publicity@cbspd.com)

#### Branches

- **Bengaluru:** Seema House 2975, 17th Cross, KR Road, Banasankari 2nd Stage, Bengaluru 560 070, Karnataka, India  
Ph: +91-80-26771678/79 Fax: +91-80-26771680 e-mail: [bangalore@cbspd.com](mailto:bangalore@cbspd.com)
- **Chennai:** 7, Subbaraya Street, Shenoy Nagar, Chennai 600 030, Tamil Nadu, India  
Ph: +91-44-26680620, 26681266 Fax: +91-44-42032115 e-mail: [chennai@cbspd.com](mailto:chennai@cbspd.com)
- **Kochi:** 42/1325, 1326, Power House Road, Opp KSEB, Power House, Ernakulam 682 018, Kerala, India  
Ph: +91-484-4059061-65/67 Fax: +91-484-4059065 e-mail: [kochi@cbspd.com](mailto:kochi@cbspd.com)
- **Kolkata:** 147, Hind Ceramics Compound, 1st Floor, Nilgunj Road, Belghoria, Kolkata 700 056, West Bengal, India  
Ph: +033-25633055, 033-25633056 e-mail: [kolkata@cbspd.com](mailto:kolkata@cbspd.com)
- **Lucknow:** Basement, Khushnuma Complex, 7-Meerabai Marg (Behind Jawahar Bhawan), Lucknow 226 001, UP, India  
Ph: 0522-4000032 e-mail: [tiwari.lucknow@cbspd.com](mailto:tiwari.lucknow@cbspd.com)
- **Mumbai:** PWD Shed, Gala no. 25/26, Ramchandra Bhatt Marg, Next to JJ Hospital Gate no. 2, Opp. Union Bank of India, Noorbaug Mumbai 400 009, Maharashtra, India  
Ph: 022-66661880/89 Mob: 0-8424005858 e-mail: [mumbai@cbspd.com](mailto:mumbai@cbspd.com)

#### Representatives

- **Hyderabad** 0-9885175004
- **Jharkhand** 0-9811541605
- **Nagpur** 0-9421945513
- **Patna** 0-9334159340
- **Pune** 0-9623451994
- **Uttarakhand** 0-9716462459

Printed at Goyal Offset Works Pvt. Ltd, Haryana, India

#### Disclaimer

Science and technology are constantly changing fields. New research and experience broaden the scope of information and knowledge. The author has tried his best in giving information available to him while preparing the material for this book. Although, all efforts have been made to ensure optimum accuracy of the material, yet it is quite possible some errors might have been left uncorrected. The publisher, the printer and the author will not be held responsible for any inadvertent errors, omissions or inaccuracies.

*to*  

---

*my wife, Vasu*  
*and*  
*daughters Medha and Anagha*



## Preface to the Third Edition

Oral and maxillofacial radiology has made fascinating advances over the years. Even if the basics of the anatomy, pathology and its radiographic presentation have remained unchanged, great changes have occurred in the imaging modalities and in techniques and interpretation. The recent advances and their significance in oral radiology have been included in this edition. It is said that a picture is worth a thousand words, and hence as far as possible newer images have been included to explain and illustrate the radiographic presentation of numerous pathological conditions.

As with the previous editions, no claim is made regarding originality of the material included in this book. The last two editions of this book were well received and appreciated by the exam going undergraduate students. It is important to present the basic theory of the subject in a simplified manner so that the students can grasp the fundamentals. At the same time, advances in the subject also have to be learnt by the student. An honest effort has been made of striking a balance between the basic and advanced aspects of the subject, in this edition.

As the time available for the last minute preparation is short, students want the theory material to be concise, easy to understand and to reproduce. An effort is made in this book to include the subject matter from various standard textbooks and present it in a student friendly manner.

I am deeply indebted to my teachers and mentors from whom I have learnt this subject and benefitted at each stage in life. Late Dr Girish Merchant was an honorary professor, a royal personality, a teacher with deep practical knowledge and an excellent human being, who set an example for us with his dignified demeanour.

Late Dr Aspi Surveyor who unfortunately passed away last year, i.e. in 2020, was indeed a teacher par excellence and it was my privilege to be both his UG and PG students. As a PG guide, he expected nothing but perfection from his students and it was indeed a marvel to us that he never missed his lectures and PG seminars and it was quite evident that he practically knew the great texts by HM Worth, and Burket inside out and could reproduce verbatim any subject matter. As students, we struggled to keep up to his expectations answer his complex and logically reasoned questions.

Dr Ani John though junior to Surveyor sir was our teacher and professor and was very kind in overlooking our faults and lacunae in



our knowledge. She was a master of her subject and unfortunately had a short tenure as a Professor and Dean at GDC & H Mumbai, as God snatched her away from us. Dr RN Mody of GDC & H Mumbai and later of Nagpur was also senior staff member and a guiding force who guided me in the initial phase of teaching career and I am indebted to him.

Dr SA Jakhi and Dr Bharati Parekh from Nair Hospital Dental College are both well-established academicians and teachers of great merit and caliber and we had the opportunity as postgraduate students to interact and learn from them.

All the editions of this book were possible only because of the knowledge selflessly imparted by these benevolent *Gurus* in our subject of oral medicine and radiology.

As I tried to make the third edition more up-to-date, I took help of many staff members and postgraduate students of GDC & H and without their selfless help this edition would have been impossible. Dr Eswaran Ramaswamy has been a great help and always magnanimously shared many interesting cases. Dr Sonali Kadam has been equally supportive and I am indebted to both of them for their help. I have heavily relied upon Dr Shraddha Jugade for going through the initial manuscript and also for the tedious task of making the Index. Dr Aparajita Praharaj helped with the tedious task of proofreading and both Shraddha and Aparajita suggested valuable alterations for which I am grateful to them.

At Government Dental College and Hospital, the Deans Dr Mansing Pawar, and Dr Vivek Pakhmode were very encouraging, helpful and supportive and I feel indebted to them for all the cooperation.

Almost all the cases included in this book were from the patients who attended the busy OPD of GDC & H Mumbai and were handled by the postgraduate students and I am extremely grateful to all the postgraduate students who helped me with these cases. I am also indebted to the patients for their unconditional cooperation.

I express deep appreciation to Shri YN Arjuna of CBS Publishers for his constant guidance and encouragement. I am deeply grateful to Mr Jinay and Ms Ritu of CBS Editorial team.

**HR Umarji**

## Preface to the First Edition

*Ideals are like little stars, We cannot reach them  
But we benefit by their presence.*

—John Le Carre

No claim is made regarding the originality of the text in **Concise Oral Radiology**. In fact the idea behind this publication was to present important aspects of oral radiology available in various standard textbooks in a nutshell so as to help the undergraduate students, too hard pressed for time, to refer to many textbooks.

I have drawn heavily on the knowledge, experience and teachings of great stalwarts in oral radiology in India, Dr GJ Merchant, DrAB Surveyor, Dr Jakhi, D Ani John, Dr BK Parikh and Dr RN Mody. Under their guidance I have learnt this subject. These stalwarts permitted me to sit near their feet, but should not be blamed for my simplicity.

The efforts required to publish a book, however concise, was too cumbersome for a lazy man like me, too skeptical of his knowledge. Dr Easwaran Ramaswami, however, did not have the shortcomings of his teacher and spared no efforts to accomplish the task. I shall be forever grateful to him for all his help and tireless efforts.

There is always a need for a detailed and in-depth study of any topic and for such reasons the reference books are mentioned at the end of the chapters. To maintain the text brief and succinct, I have been ruthless in slashing large portions of information and may also be accused of oversimplification. Despite these and several other shortcomings, I venture to hope that this text will not make an unwelcome or unworthy addition to an ever-increasing list of textbooks in the subject of oral radiology.

I am indeed fortunate to be associated with Government Dental College and Hospital (GDC & H), Mumbai, as a student and a teaching staff and my contributions in this text (radiographs, etc.) are only because I happened to work in this great institution and collected the material from the patients attending GDC & H OPD. I have always felt encouraged in this institute and feel proud to belong to it.

I have been constantly encouraged and inspired by the students of GDC & H (both undergraduate and postgraduate) and the staff members. I am indebted to them as I have learnt so much from interactions with them.

I am also grateful to Miss Jyoti Madaan for excellent art work and Mr. Balram Solanki and BR Sharma of CBS Publishers & Distributors for all their help.

**HR Umarji**



## Contents

*Preface to the Third Edition* vii

*Preface to the First Edition* ix

---

### **1. Introduction and Basic Radiation Physics** **1**

- Electromagnetic spectrum 3
- Construction and working of X-ray machine 5
- Factors affecting the radiographs 14

### **2. Radiobiology** **37**

- Radiation effects and classification 38
- Radiation protection 51

### **3. Ideal Radiograph and Radiographic Techniques** **58**

- Rules of projection geometry 58
- Periapical radiographs 66
- Faults/blemishes artifacts in radiographs 73
- Occlusal Radiography 81
- Extraoral radiography 86

### **4. Anatomical Landmarks** **114**

- Anatomic landmarks of the maxilla 118
- Anatomical landmarks of the mandible 126

### **5. Digital Imaging** **134**

- Digital image detectors 135
- Digital subtraction radiography 139

### **6. Principles of Radiographic Interpretation** **140**

- Image analysis 141
- Commandments of radiographic interpretation 147

### **7. Dental Caries and Periapical Pathology** **149**

- Limitations of radiography in diagnosing dental caries 149
- Radiographic appearance of caries 151
- Differential diagnosis of dental caries 154
- Periapical lesions 157

<b>8. Periodontal Diseases</b>	<b>165</b>
Limitations of radiography	165
Radiographic findings in periodontal disease	167
<b>9. Osteomyelitis</b>	<b>175</b>
Etiology	175
Pathogenesis	176
Radiographic features	177
Garre's osteomyelitis	183
<b>10. Cysts of the Jaws</b>	<b>187</b>
Characteristic features of cyst	188
Radicular cyst	188
Dentigerous cyst	192
Odontogenic keratocyst	196
<b>11. Odontomes and Benign Tumors</b>	<b>213</b>
Classification of odontomes	213
Differences between benign and malignant tumors	219
WHO classification of odontogenic tumors	221
<b>12. Malignant Tumors</b>	<b>254</b>
Modes of spread of malignancies	255
The TNM staging	257
Squamous cell carcinoma	260
Osteosarcoma	268
<b>13. Developmental Disorders Affecting the Teeth</b>	<b>277</b>
Amelogenesis imperfecta	284
Dentinogenesis imperfecta	286
Dentine dysplasia	287
<b>14. Salivary Gland Diseases</b>	<b>290</b>
Classification of salivary gland diseases	291
Imaging modalities for salivary gland diseases	292
Sialographic appearance in various diseases	295
<b>15. TMJ Disorders</b>	<b>313</b>
Classification of TM joint disorders	313
Ankylosis	326
Internal disc derangement	330
Myofascial pain dysfunction syndrome	334

**16. Diseases of Maxillary Sinus 339**

- Maxillary sinusitis 342
- Oroantral fistula 345
- Extrinsic cysts and tumours 347
- Squamous cell carcinoma of the sinus 349

**17. Fibro-Osseous and other Bone Lesions 353**

- Fibrous dysplasia 353
- Cherubism 358
- Florid osseous dysplasia 359
- Ossifying fibroma 361
- Paget's disease 361

**18. Advanced Imaging Modalities for Maxillofacial Region 366**

- Xeroradiography 366
- Ultrasonography 366
- CT scans 368
- Cone beam computed tomography 369
- Magnetic resonance imaging 373
- Fusion imaging 376

Appendix I: Radiographic Differential Diagnosis 377

Appendix II: Radiographic Appearances 383

*Index*

**385**