

Volume 2

Volume 2

Volume 2

Exam-Oriented Anatomy Questions and Answers **Second Edition**

Medical Council of India has reduced the duration of First Year MBBS by 6 months and introduced new pattern of questions which include long answer questions, short notes, short answer questions, clinical problems and multiple choice questions. Students are expected to know all the topics as well as specific information and minute, relevant details having clinical importance.

There is no source for the definition and the extent of contents of the various terms used in the theory questions. The author has extensively discussed these terms with eminent anatomists in India and attempted to define these terms. He is aware of the limitations and has high regard about others' views.

This four-volume book attempts to provide unique solutions to these problems for the benefit of the readers studying human anatomy and preparing for their examinations.

Contents of the Four Volumes	
Volume 1	• Abdomen
• General Anatomy	• Pelvis
• General Histology	Volume 3
• Lower Limb	• Head
• Upper Limb	• Neck
Volume 2	• Face
• General Embryology	Volume 4
• Genetics	• Brain
	• Thorax

Salient features of the four volumes

- The book is written using short and simple sentences.
- Four types of questions are discussed: LAQs (Long Answer Questions), SN (Short Notes), SAQs (Short Answer Questions), and OLA (One Line Answers).
- The information given in italics is the information required to answer the MCQs.
- The answers are written in the form of points by using indentation.
- Tables are introduced to save the time and display the information for immediate reference for the students and examiners.
- The relevant, simple, linear informative diagrams are drawn with the respective colours.
- Important key words, which help to memorize the subject without taxing the memory, are given.
- At the end of the book separate indexes have been given.

Shoukat N Kazi MS (Anatomy), DTCD, BSc, LLB

is currently Principal, Dr Tasgaonkar Medical College and Research Centre, Karjat, and has been Principal, Prasad Institute of Medical Sciences, Lucknow, UP. He has served as Professor of Anatomy at Rajashree Medical Research Institute, Bareilly; SRM Medical College Hospital and Research Centre, Chennai; Chennai Medical College Hospital and Research Centre, Trichy; Dr DY Patil Medical College, Pimpri; and Dr DY Patil Vidyapeeth (Deemed to be University), Pimpri, Pune.

Dr Kazi is one of the popular and enthusiastic teachers of anatomy. He started his teaching profession from 1986 and dedicated completely from 1996. He has coached thousands of students.

He makes the subject very simple and appealing to the students. His efforts are to make the subject memorable. He constantly updates himself academically, spiritually and socially. He has special interest in implementing new methods of learning. His mission is to reach all the medical students and make them anatomyphilic. He is a strong positive thinker and motivator.

Students from all over world attend his Kazi Medical Classes, Pimpri, for studies. It is equipped with histology slides, bone sets, models of all topics of gross anatomy and embryology.

He was called as a guest speaker in 46 colleges in Maharashtra, Karnataka, Uttar Pradesh, Gujarat, Kerala and Tamil Nadu; about 8000 students who took the benefit of his guest lectures. He has conducted over 13 workshops of one to five day interactive sessions on various anatomic regions, benefitting about 2000 students.

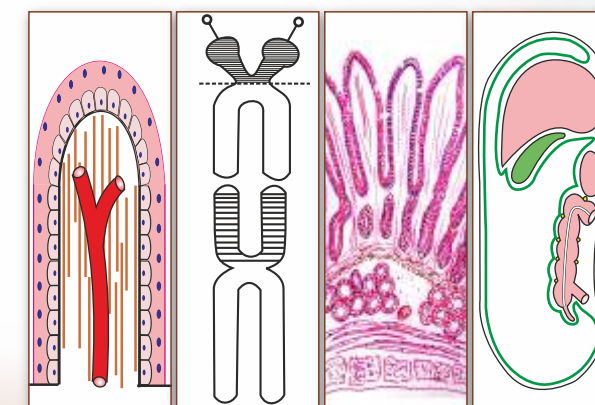
Exam-Oriented Anatomy Questions and Answers

Second Edition

Kazi



Exam-Oriented Anatomy Questions and Answers **Second Edition**



- General Embryology
- Genetics
- Abdomen
- Pelvis



Available free on **CBSiCentral App**
High-value animation videos of human anatomy

Shoukat N Kazi



CBS Publishers & Distributors Pvt Ltd

4819/XI, Prahlad Street, 24 Ansari Road, Daryaganj, New Delhi 110 002, India
E-mail: delhi@cbspd.com, cbspubs@airtelmail.in; Website: www.cbspd.com
New Delhi | Bengaluru | Chennai | Kochi | Kolkata | Mumbai
Bhopal | Hyderabad | Jharkhand | Nagpur | Patna | Pune | Uttarakhand

ISBN: 978-93-



Dedicated to Education

CBS Publishers & Distributors Pvt Ltd

Volume 2

Exam-Oriented

Anatomy

Questions and Answers

Second Edition

- General Embryology
- Abdomen

- Genetics
- Pelvis

Shoukat N Kazi MS (Anatomy), DTCD, BSc, LLB

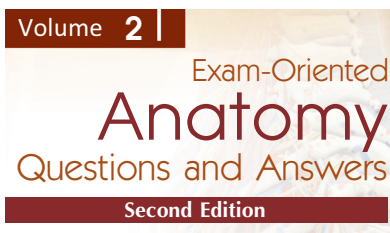
Principal, Dr Tasgaonkar Medical College and
Research Centre, Karjat, Maharashtra
Ex-Principal, Prasad Institute of Medical Sciences
Banthara, Lucknow (UP)
Ex-Professor

Rajshree Medical Research Institute, Bareilly
SRM Medical College Hospital and Research Centre, Potheri, Chennai
Chennai Medical College Hospital and Research Centre, Trichy
Dr DY Patil Medical College, Pimpri, Maharashtra
Dr DY Patil Vidyapeeth (Deemed to be University), Pimpri, Pune



CBS Publishers & Distributors Pvt Ltd

New Delhi • Bengaluru • Chennai • Kochi • Kolkata • Mumbai
Hyderabad • Jharkhand • Nagpur • Patna • Pune • Uttarakhand



Disclaimer

Science and technology are constantly changing fields. New information, research and experience broaden the scope of knowledge. The author has tried his best in giving information available to him while preparing the material for this book. Although all efforts have been made to ensure optimum accuracy of the material, yet it is quite possible some errors might have been left uncorrected. The author, the publisher and the printer will not be held responsible for any inadvertent errors or inaccuracies.

ISBN: 978-93-90046-13-3

Copyright © Author and Publisher

Second Edition: 2021

First Edition: 2005

All rights reserved. No part of this book may be reproduced or transmitted in any form or by any means, electronic or mechanical, including photocopying, recording, or any information storage and retrieval system without permission, in writing, from the author and the publisher.

Published by Satish Kumar Jain and produced by Varun Jain for

CBS Publishers & Distributors Pvt Ltd

4819/XI Prahlad Street, 24 Ansari Road, Daryaganj, New Delhi 110 002, India.

Ph: 011-23289259, 23266861, 23266867 Fax: 011-23243014 Website: www.cbspd.com

e-mail: delhi@cbspd.com; cbspubs@airtelmail.in

Corporate Office: 204 FIE, Industrial Area, Patparganj, Delhi 110 092

Ph: 011-4934 4934

Fax: 011-4934 4935

e-mail: publishing@cbspd.com; publicity@cbspd.com

Branches

• **Bengaluru:** Seema House 2975, 17th Cross, K.R. Road, Banasankari 2nd Stage, Bengaluru 560 070, Karnataka

Ph: +91-80-26771678/79

Fax: +91-80-26771680

e-mail: bangalore@cbspd.com

• **Chennai:** 7, Subbaraya Street, Shenoy Nagar, Chennai 600 030, Tamil Nadu

Ph: +91-44-26260666, 26208620

Fax: +91-44-42032115

e-mail: chennai@cbspd.com

• **Kochi:** 42/1325, 1326, Power House Road, Opp. KSEB, Power House, Ernakulam 682018, Kochi, Kerala

Ph: +91-484-4059061-65

Fax: +91-484-4059065

e-mail: kochi@cbspd.com

• **Kolkata:** No. 6/B, Ground Floor, Rameswar Shaw Road, Kolkata 700014 (West Bengal), India

Ph: +91-33-2289-1126, 2289-1127, 2289-1128

e-mail: kolkata@cbspd.com

• **Mumbai:** 83-C, Dr E Moses Road, Worli, Mumbai 400018, Maharashtra

Ph: +91-22-24902340/41

Fax: +91-22-24902342

e-mail: mumbai@cbspd.com

Representatives

• **Hyderabad**

0-9885175004

• **Jharkhand**

0-9811541605

• **Nagpur**

0-9421945513

• **Patna**

0-9334159340

• **Pune**

0-9623451994

• **Uttarakhand**

0-9716462459

Printed at Nutech Print Services, Faridabad, India

To

My parents

Late Haji Nizamsaheb K Kazi

Late Hajjan Mrs Jainnabbi N Kazi

My wife Kamartaj

For tolerating my preoccupation

And my daughter Sadiya

For understanding me

And

Students

For appreciating my way of teaching and
providing me a continuous stimulus to write the book

Foreword to the Second Edition

Prof SN Kazi's *Exam-Oriented Anatomy*, 2nd edition, is going to compete with all other books on the subject available in the market. It is not only simple, digestible and very attractive but also exceptionally informative and rich into the extent that even heavy textbooks do not carry so much information. I have great respect for him, for his dedication and lust for writing book. I wish him all the best.



Dr Nafis Ahmad Faruqi

Professor
Department of Anatomy
Jawaharlal Nehru Medical College
Aligarh Muslim University, Aligarh, UP
India

Foreword to the First Edition

Prof SN Kazi's book is intended to help medical students rapidly master complex intricacies of human anatomy that is essential to clinical care.

This book was written to fulfill the need for a brief, but readable, summary of the relevant anatomy, with succinct notes on applied anatomy wherever indicated. It addresses the diverse and mounting need of medical students preparing for professional examinations. The text will not only enhance the knowledge to an extent sufficient to satisfy the examiners but will also equip the readers with the necessary understanding of applied anatomy for future practice. A recurring problem in medical education is the common inability of the students to relate the large body of factual knowledge to practical application in their future clinical training. A commendable endeavour has been made by Prof Kazi to bridge the gap between rote anatomy and clinical relevance. The mnemonics and humour in this book do not intend any disrespect for anyone, rather they are employed as an educational device, as it is well known that the best memory techniques involve the use of ridiculous association. Stephen Goldberg in his unique book titled "Clinical Neuroanatomy Made Ridiculous Simple" has already demonstrated their efficacy superbly.

Books	LAQs	SAQs	SNs	Keywords	Line diagrams	Tables
Above diaphragm	93	20	156	91	254	47
Below diaphragm	47	38	125	49	254	47

This book is not designed to replace standard reference textbooks, but rather is to be read as a companion text before appearing in an examination. This will enable the student to gain an overall perspective of essential anatomy.

My best wishes for the success of this endeavour which merits appreciation.

Prof (Dr) Mahdi Hasan

MBBS, MS (Hons.), FICS, FAMS, PhD, DSc, FNA

Professor Emeritus

INSA Senior Scientist, Department of Anatomy

Chhatrapati Shahuji Maharaj Medical

University (King George's Medical University)

Lucknow, UP (India)

Formerly

Professor and Chairman, Department of Anatomy and

Founder Director

Interdisciplinary Brain Research Center

Dean, Principal and Chief Medical Superintendent Jawaharlal Nehru Medical College, Aligarh

Muslim University, Aligarh, UP (India)

Foreword to the First Edition

All the medical colleges in the state of Maharashtra were affiliated to eight different conventional universities in the state up to 1997. After the establishment of Maharashtra University of Health Sciences in the state in 1998, all of them were affiliated to this single state level university. Previously syllabi and pattern of examination were different but the new pattern (1 + 1½ + 2 years) of curriculum recommended by the Medical Council of India while the conventional universities were following the old (1½ + 1½ + 1½ years) pattern. First time in the examination, LAQ, SAQ and MCQ patterns were introduced by MUHS. On the background of the reduced duration for both students (for learning) and teachers (for teaching) of I MBBS, there was a need for examination-oriented revision book.



It is really a great pleasure for me to introduce this book on human anatomy written by one of my ex-colleagues, Dr SN Kazi. I have gone through the manuscript of this book which adequately covers the subject. Usually students have to purchase separate books for anatomy, histology, embryology, general anatomy, genetics, etc. Dr. Kazi has tried to cover all these branches in simple language with the help of computerized line diagrams. It is designed to meet the need of the undergraduate exam going students. Most of the information are given in tabular forms, easy to compare and remember and clinical applications of the subject have been touched adequately.

The book speaks the long experience of the author in the subject and will minimize the stress and strain of a medical student during pre-examination period. I congratulate the author for this venture and wish the book great success.

Shingare PH

Professor and Head, MS
Department of Anatomy
Grant Medical College and
Sir J J Group of Hospitals
Byculla, Mumbai
Director of Medical Education and Research,
Maharashtra
Ex-Dean, Faculty of Medicine, North Maharashtra University
Ex-Controller of Exam, MUHS, Nashik
Ex-Chairman, BoS Preclinical, MUHS, Nashik
Member of BoS Preclinical Faculty of
Medicine and Faculty of Dentistry, MUHS
Ex-Vice Dean UG, Grant Medical College, Mumbai
Ex-Vice Dean PG, Grant Medical College, Mumbai

Preface to the Second Edition

I am very much excited to present the 2nd edition. Initially I thought it will not take much time, but as I started preparing for the 2nd edition, new ideas start clouding in my mind and the ideas went on increasing.

In the last 15 years, I received many feedbacks about inadequate answers, too much simplicity of the text, too many mnemonics. I reviewed various books on memory techniques and came with various ideas. I am happy to share the experiences of teaching in different parts of country. In north and central part of India, the main barrier is writing skills. The students are either from Hindi medium or language of regional medium. The immediate challenges after joining medical course is communication and managing vast syllabus.

I have made an attempt to write in very simple language. In the first reading only, the student should be able to understand the contents. I have used the symbols for most of the words. It is rightly said "A picture is equal to thousands of sentences. A cartoon is worth of thousands of pictures". **Visual memory** works better for the pictures than the texts. **Colours** have deep impact than black and white. Kinesthetics have far more effect as compared to auditory and visual. Combined effects of auditory, visual and kinesthetic have profound effect on memory.

A sincere attempt is made not only to give the contents of the subject, but also to make the student remember the subject by using various techniques. The author has attended the lectures of the many anatomists, studied the delivery of lectures. He has picked up the concepts and presented in the form of book. The book is collections of techniques used by well-known anatomists of India.

Memory Technique

1. **Association memory**
 - A. **Day-to-day examples:** City bus for ascending and descending tracts.
 - B. **Association of letters**
 - a. After "C" to recollect the nuclei of cerebellum.
 - b. ABCD for the normal constrictions of oesophagus
 - c. **Ruffini** for **red** and **Krause** for **cold** receptor. This was contributed by **Dr Nandedkar madam**, a senior anatomist from AFMC.
 - C. Association of digit 10 for 4 important information of oesophagus.
 - a. Length of oesophagus
 - b. Constrictions of oesophagus
 - c. Opening in diaphragm at 10th thoracic vertebra
 - d. First mark on the paediatric Ryles tube.
2. **Use of one's hand for representation of various structures and relations**
 - A. Branches of splenic artery
 - B. Intermuscular spaces
 - C. Use of 3 fingers for transpyloric plane at lower 1st lumbar
 - D. Branches of basilar artery
 - E. Tributaries of coronary sinus
3. **Framing the rules for registration of information**
 - A. Rule of alternate framed by honorable late Padmashree Dr Mahdi Hasan to
 - a. Recollect the

- I. Paired and unpaired branches of abdominal aorta
- II. Peritoneal and retroperitoneal structures.
- b. Dropping the alternate letters to recollect the names of extrapyramidal tracts.
- B. Use of juggle “Carotico parotico Tonsilii Tympani” to complete the distribution of glossopharyngeal nerve. This is contributed by famous anatomist and surgeon Dr Kadasne, author of many textbooks.
- C. Use of fingers to differentiate to walls of artery and vein. This is contributed by Dr Krishna Garg madam, editor of world famous textbook *BD Chaurasia’s Human Anatomy*.
- 4. Link technique
- 5. Meaning of words
 - A. Dura—hard, durable B. Dia—in between
- 6. Peg technique Mnemonic—Laila Loves Majnu for the branches of lateral cord of brachial plexus.
- 7. Simile: Course of hepatic artery represented by badly driven nail. Referred from Surgical Synopsis.
- 8. Picture mnemonic to represent Cri du chat syndrome.
- 9. Stories
 - A. A girl from South and boy from Chandigarh had friendship in Jaipur. They got married in Jaipur but marriage could not survive because of different culture and food habit. They got divorced. Boy went back to Chandigarh and got married in own community. This story is appealing for origin, course and distribution of accessory nerve. The story was fabricated by Dr Aruna Mukherjee, a well-known anatomist.
 - B. A story of water pipe for the course of internal pudendal artery.
- 10. Text in simple English.
- 11. Things added with religious sentiments: Dr Mysorekaran eminent, Professor of AFMC, used to teach functions of thalamus by giving simile of thalamus to God Nandi and cerebrum with Lord Mahadev.
- 12. The concept of **mind mapping**, introduced by Tony Buzan, is used to depict the branches of brachial plexus.
- 13. Use of celebrities
 - A. Mary Kom—action of serratus anterior
 - B. Ajay Devgn for overriding of horse to make understand the features of Fallot’s tetralogy.
- 14. Use of key **advertisements** as the keywords—**PRO V** for features of Fallot’s tetralogy.
- 15. Use of airplane and navies for reminding suprascapular artery and nerve, above and below the suprascapular ligament.
- 16. Use of pictures of anatomy students whose passion is body building. A photo of Wasim Khan is used to display the actions of sternal and clavicular head of pectoralis major.
- 17. Fruit of pine tree to show pineal body.
- 18. Use of symbols and pictures of muscles to boost the memory.

It was a feedback from the passed-out students that there is mismatch between what is taught in applied anatomy in the first year and what is expected in clinical posting. To fill up the gap, the author has reviewed the applied anatomy from physician, general surgeon, ENT surgeon, ophthalmologist, orthopaedic surgeon, and geneticist. The author has reviewed various regions from senior anatomists.

All the feedback has been meticulously rectified.

Separate boxes are introduced for the understanding of the subject and for memorization.

Shoukat N Kazi

Acknowledgements to the Second Edition

I recollect the days, when I determined to write for the second edition. I thought of getting all the books of anatomy that are freely available and accessible. I collected books from all the old book bazar in Delhi, Mumbai, Pune, Pimpri, Lucknow, Ahmedabad, Rajkot. I am very much thankful to Dr TC Singel, Professor, Department of Anatomy, Zydus Medical College, who took me to various old bookstores in Ahmedabad and made them available. He also lent me the library books. It was a great help. I could get the books which are not available in any of the college library. I am very much grateful to him.

I cannot afford to forget the continuous encouragement given by Mr Bhagwan Yadav, Chairman, Managing Director, Prasad Institute of Medical Sciences, Lucknow.

Scanning of the book was done by our office staff, namely Prajakta, Rhutuja. I am thankful to them. I need to mention the name of Mr Rehan Ansari, (HR, Prasad Institute of Medical Sciences, Lucknow) who got the books scanned in a very short time.

There were vital technical issues, because of which I was handicapped. The problems were resolved by my nephew, Mr Wahab Kabir Kazi. I am very much thankful to him.

The basic suggestions of diagrams were made by a corel artist Mr Sanjay, CBS Publishers & Distributors. I am thankful to him.

I am really lucky to have the contributions from many professors.

To start with, Mrs Jasmine Naik drew some of the diagrams in corel draw but because of her child's health she could not continue. The work was continued by Mrs Zeenat Shaikh. She really put her heart in diagrams. She learnt all the intricacies of anatomy subject and gave her 100% to make the diagrams right. She is very much concerned for the success of the book.

The repeated editing of the text and layout of diagrams, sequencing of questions, was done untiringly by Miss Parveen Shaikh and Mrs Jyoti Dhage. In addition to editing, Miss Parveen Shaikh has kept an eye on all the activities and coordinated in a very efficient way. They are the backbones of the book, without their help, the quality of the book was not possible. I am really blessed to have the staff, namely Miss Parveen Shaikh, Mrs. Jyoti Dhage and Mrs Zeenat Shaikh. Mrs Maya Bhujbal, and Mr Uday Jadiye, who have helped in minute layout of the book.

I am indebted for the help my brother Mr Kabir Kazi has extended to me. He has helped me in organizing guest lectures, workshops and made me tension free to write the book. It was a continuous support to me.

The continuous inspiration and motivation was given by my brothers Mr Shikandar, Allabaksh and Najir Kazi.

The technical support was given by Mr YN Arjuna Senior Vice-President—Publishing, Editorial and Publicity, and his team. He has understood me and helped without any hesitation.

The real financial help was extended by Mr Satish Kumar Jain, CMD, CBS Publishers & Distributors. His help was stress bursting to me. The quality of the book has reached only because of his timely help, and the patience he has shown to me. We have very good bonding for so many years.

I am really thankful from the bottom of my heart to Mr Varun Jain, Director, who is dynamic in implementing various technology in the books. The animation of neuroanatomy and upper limb and abdomen is being introduced, only because of his initiation. I owe him a lot.

The real tolerance and patience were given by my better half Mrs Kamartaj and my daughter Miss Sadiya. I did not give any time and attention to family activities. I appreciate their understanding.

Special Thanks

I am extending my sincere and special thanks to the following persons, without whom the book would not have been completed.

- **Dr PH Shingare**, Professor and Head, Department of Anatomy, Grant Medical College, Mumbai, has meticulously corrected the text and has given solutions to diagrams. He has tolerated my disturbance at odd hours in his busy schedule.
- **Dr (Mrs) Kanaklata Iyer**, Professor of Anatomy at Somaiya Medical College, Sion, Mumbai, has really given a breakthrough to the problems of diagrams. She has helped out rightly by sparing her valuable time through her busy schedule by taking keen interest. She has contributed diagrams of gross anatomy of abdomen, inferior extremity and general embryology.
- **Dr Savgaonkar**, Professor of Anatomy at BJ Medical College, Pune, has drawn histology diagrams of abdomen section. He being my close friend, understood the difficulties and offered his help by completing the diagrams in very short time.
- **Dr Anjali Dhamangaonkar**, Associate Professor, in Anatomy at GS Medical College, Mumbai, has contributed to the general embryology diagrams. It was very difficult for her to give some time. But her desire to help me has solved the problems.
- **Dr Manvikar Purushottam Rao**, Lecturer in Anatomy at Dr DY Patil Medical College, Pimpri, has drawn some of the diagrams of general histology. He is the main push for animation work.
- **Dr Kadasne DK**, the author of *Kadasne's Textbook of Anatomy (Clinically-oriented)*, has allowed me to use some of the diagrams from his book.
- **Dr Umarji**, Professor and Head, Department of Anatomy, Krishna Institute of Medical Sciences, Karad, has drawn a few diagrams of general anatomy.

Shoukat N Kazi

Contributors



Arudyuti Chowdhury MS, DGO

Associate Professor, SRM Medical College, He was my roommate at SRM Medical College, Chennai. Dr Arudyuti Chowdhury is constant motivators. He has helped me in all the activities. His word of suggestion is important for me.



Ashok Kumar Rawat MS (Ortho)

Assistant Professor, Department of Orthopedics, Associate Professor, Prasad Institute of Medical Sciences, Lucknow.

He has helped in giving fine touch of applied aspects of joint.



Gangane

Professor and Head, Department of Anatomy, Medical College, Navi Mumbai. Thank you very much for finding time for approving the contents.

Jyoti Kulkarni

Professor in Anatomy in Nepal

She has gone meticulously in all the texts and diagrams of books and given valuable suggestions. The quality of the book is definitely improved because of her suggestions. I am very much obliged and thankful for her help.



Manvikar

Professor and Head, Department of Anatomy, Padmashree, Dr DY Patil Medical College, Pimpri, Pune. Thanks very much for giving genetic inputs.

MC Srivastav

Medical Superintendent and Associate Professor of Medicine, Prasad Institute of Medical Sciences, Lucknow. He is kind enough to add EKG changes in blockage of coronary arteries.

Murugan Kutty Gopalan

BSc, MBBS, DMA (USA)



Head, Departments of Medical Illustrations, Digital Health, Clinical Skills Simulation Center and Telemedicine, Amrita Institute of Medical Sciences and Research Center, Kerala, India. He is involved in the **Simulation-Based Medical Education** in giving training in various clinical skills. He is intensely working on introducing new generation **Medical Haptics, Robotic Surgery, Cardiac-Neuro-Ortho interventional Simulaids** for the super-specialty branches in Medicine and Surgery. He has won several regional, national and international awards for his innovative illustrative works.

All histology diagrams of 2nd edition are fabricated by Dr Gopalan. Apart from contributions to the book, he is my very close friend, whose door I can knock for any help any moment. I am heavenly blessed to have a friend like Dr Gopalan.

He is courageously fighting his health issue like a warrior. I know him since last 15 years. He is very much energetic. The energy and enthusiasm have increased many folds after he met his health issue. I think adverse situations boost his energy. I do not know from where he gets energy to do such activities. I pray God to give him long healthy life.



Nayana Karodpati

Professor (ENT, DYPMC), Pimpri, Pune

She edited the text and added the topics which are of clinical importance. Hearty thanks for the help.



P Vatsalaswamy MD

Director of DYPMC, Pimpri, Pune

In spite of her busy administrative activities and family commitments, she could spare time and could help me. I am very much obliged.

She has reviewed superior extremity. She has gone in details of each word of text and given the feedback.



Salamat Khan

Professor of Surgery, Prasad Institute of Medical Sciences, Lucknow. Dr Salamat Khan has voluntarily helped me in reviewing applied anatomy of limbs, abdomen, head, neck, face, thorax, and brain. He has gone word to word and

gave the suggestions. I salute him for his help.



Sunita Nayak

Assistant Professor

All India Institute of Medical Sciences, Patna



Ubaidur Rehman

Medical Superintendent, Prasad Institute of Medical Sciences, Lucknow. He has helped in updating ophthalmology chapters. I was lucky to be associate with him.



Vaishali Bharambe MD, PhD

Ex-professor, DY Patil Medical College, Pimpri, Pune

Presently she is working as a Professor and Head, Symbiosis Medical College, Pune. She was very much busy in preparation of PhD. In spite of her hectic schedule, she could review the diagrams of lower limb. I owe her.



Vinod Kathju

Former additional Principal, Dr SN Medical College, Jodhpur

I am very much thankful for his kind guidance and contribution

Abdomen: Animation

Sr. No.	Duration	Question	Topic
AA1	9.56	LAQ-12	Introduction of abdominal aorta
AA2	3.45	SN-42	Inferior phrenic artery
AA3	3.59	SN-35, LAQ-9	Coeliac trunk
AA5	5.24	SN-33	Splenic artery
AA10	3.12	SN-50	Middle suprarenal artery
AA28	4.00	LAQ-12	Cartoon of abdominal aorta
AA29	4.00	OLA-18, SN-41, LAQ-12, SAQ-7	Technique to find vertebral level of branches of abdominal aorta
AA30	4.09	SAQ-7, SAQ-8	Technique to find level of suprarenal, renal, lumbar and median sacral artery
AA31	4.40	LAQ-24	Simile of internal pudendal artery

These high-value animation videos are available on **CBSiCentral App** through scratch code. Please see the front inner cover for obtaining access code.

Contents

<i>Foreword to the Second Edition</i> by Dr Nafis Ahmad Faruqi	<i>iv</i>
<i>Foreword to the First Edition</i> by Prof (Dr) Mahdi Hasan	<i>v</i>
<i>Foreword to the First Edition</i> by Shingare PH	<i>vi</i>
<i>Preface to the Second Edition</i>	<i>vii</i>

Section 1 General Embryology

1. Cell Division	3	SN-15	Umbilical cord	28	
SN-1	Mitosis	3	SN-16	Intra-embryonic mesoderm (secondary mesoderm)	29
SN-2	Meiosis	5	SN-17	Allantois	31
2. Spermatogenesis	10	SAQ-3	Septum transversum	32	
SN-3	Spermatogenesis	10	6. The Placenta	33	
SAQ-1	Spermiogenesis	12	SN-18	Implantation	33
SAQ-2	Sperm	12	SN-19	Blastocyst	35
SN-4	Capacitation of sperm	13	SN-20	Decidua	35
SN-5	Oogenesis	13	SN-21	Placenta	37
3. The Menstrual Cycle	15	SN-22	Types of placenta depending upon shape	39	
SN-6	Graafian follicle	15	SN-23	Types of placenta depending upon attachments	40
4. Formation of Germ Layers	17	SAQ-4	Placenta praevia	41	
SN-7	Fertilization	17	SN-24	Chorion	43
SN-8	Amnion	19	SN-25	The maternal-foetal barrier	44
SN-9	Yolk sac	20	7. Urogenital System	46	
SN-10	Primitive streak	22	SN-26	Coelomic wall epithelium	46
SN-11	Somites	24	SAQ-5	Surface ectoderm epithelium	47
SN-12	Trophoblast	25	8. Nervous System	49	
5. Embryonic Disc	26	SN-27	Neural crest	49	
SN-13	Notochord	26			
SN-14	Connecting stalk	27			

Section 2 Genetics

9. Chromosomes and their Aberrations	53	SN-9	Klinefelter syndrome (47 XXY)	63	
SN-1	Gene	53	SN-10	Cri du chat syndrome (5p-)	65
SN-2	Barr body (sex chromatin)	54	SN-11	Nondisjunction	67
SN-3	Structure of chromosome	55	SN-12	Aneuploidy	68
SN-4	Classification of chromosomes	57	SN-13	Spectral karyotyping (Sky)	68
SN-5	Chromosomal aberrations	57	SN-14	What are genetic disorders?	69
SN-6	Chromosome banding	59	10. Mendelian Genetics	71	
SN-7	Trisomy 21	60	SN-15	Autosomal dominant inheritance	71
SN-8	Turner syndrome (45 X)	62	SN-16	Autosomal recessive inheritance	72
			SN-17	X-linked recessive traits	73

Section 3 Abdomen

- 11. Introduction and Osteology 77**
- SN-1 Spina bifida 77
 SAQ-1 Sacral hiatus 78
- 12. Anterior Abdominal Wall 80**
- SN-2 Transpyloric plane (Addison's plane) 80
 OLA-1 Sites of portocaval anastomoses 82
 SAQ-2 Caput medusae 83
 SN-3 Inguinal ligament 84
 SN-4 Rectus abdominis 85
 LAQ-1 Rectus sheath 85
 OLA-2 Name the contents of inguinal canal in male 88
 OLA-3 Name the contents of inguinal canal in female 88
 LAQ-2 Inguinal canal 89
 OLA-4 Lacunar ligament 93
 OLA-5 Attachments to pubic tubercle 94
 SAQ-3 Superficial inguinal ring 94
 SAQ-4 Deep inguinal ring 95
 SAQ-5 Coverings of spermatic cord 95
 SN-5 Spermatic cord 96
 SN-6 Hesselbach's triangle (trigonum inguinale—inguinal trigone) 97
 OLA-6 What is inguinal hernia? 98
 SN-7 Inguinal hernia 98
 SN-8 External oblique muscle of anterior abdominal wall 99
 SN-9 Transversus abdominis muscle 100
- 13. Male External Genital Organs 102**
- SN-10 Histology of testis 102
 SN-11 Descent of testis 103
 SN-12 Thermoregulation of testis 105
 SN-13 Blood supply of testis 105
 SN-14 Development of testis 106
 SAQ-6 Epididymis 108
 SN-15 Layers of scrotum 108
 LAQ-3 Testis 109
- 14. Abdominal Cavity and Peritoneum 113**
- SN-16 Peritoneal reflection 113
 SN-17 Foramen of Winslow (auditus to lesser sac, epiploic foramen) 113
 SN-18 Lesser sac (omental bursa) 114
 SN-19 Morison's pouch 117
 SN-20 Douglas' pouch/pouch of Douglas (rectouterine pouch) 118
- 15. Abdominal Part of Oesophagus and Stomach 120**
- SN-21 Blood supply of stomach 120
 OLA-7 Bare areas of stomach 121
 SN-22 What is the surface mucus cells and how do they differ from neck mucus cells in stomach? 122
- OLA-8 Differentiate between fundus and pylorus of stomach histologically 123
 LAQ-4 Stomach 123
 SN-23 Stomach bed 131
 SN-24 Oesophageal varices 132
- 16. Small and Large Intestines 134**
- SN-25 Relations of 1st part of duodenum 134
 SN-26 Relations of 2nd part of duodenum 135
 SN-27 Relations of 3rd part of duodenum 136
 SN-28 Relations of 4th part of duodenum 137
 OLA-9 Peritoneal recesses around duodenum 137
 LAQ-5 2nd part of duodenum 138
 SN-29 Duodenal cap 143
 SN-30 Ligaments of Treitz (suspensory muscle of duodenum) 143
 SN-31 Meckel's diverticulum 144
 SN-32 Differences between jejunum and ileum 145
 OLA-10 Peritoneal recesses around caecum 146
 LAQ-6 Caecum 146
 OLA-11 McBurney's point 149
 LAQ-7 Appendix 149
- 17. Large Blood Vessels of the Gut 155**
- OLA-12 Branches of splenic artery 155
 SN-33 Splenic artery 155
 LAQ-8 Inferior mesenteric artery 157
 SN-34 Obturator artery 160
 OLA-13 Enumerate the branches of coeliac trunk 162
 SN-35 Enumerate the branches of coeliac trunk 162
 LAQ-9 Coeliac trunk (coeliac axis, coeliac artery) 163
 SN-36 Left gastric artery 166
 OLA-14 Branches of superior mesenteric artery 168
 SN-37 Enumerate the branches and distribution of superior mesenteric artery 169
 LAQ-10 Superior mesenteric artery 169
 SN-38 Marginal artery 173
 LAQ-11 Portal vein 174
 OLA-15 Enumerate the branches of hepatic artery (hepatic artery proper) 179
 SN-39 Hepatic artery proper 179
 OLA-16 Calot's triangle 180
 OLA-17 Branches of common hepatic artery 181
 SN-40 The common hepatic artery 181
 OLA-18 Enumerate the branches of abdominal aorta 183
 SN-41 Abdominal aorta 184
 SN-42 Inferior phrenic arteries 186
 LAQ-12 Abdominal aorta 188
 SAQ-7 What is the vertebral level of suprarenal, renal, lumbar and median sacral arteries 193

- SN-43 Median sacral artery 196
 SAQ-8 What are the unpaired and ventral branches of abdominal aorta? 198
- 18. Extrahepatic Biliary Apparatus 199**
- LAQ-13 Extrahepatic biliary apparatus 199
- 19. Spleen, Pancreas and Liver 205**
- OLA-19 Enumerate the functions of spleen. Give two causes of its enlargement 205
 SN-44 Blood circulation in spleen 205
 LAQ-14 Spleen 206
 SN-45 Relations of liver 211
 OLA-20 Portal lobule 212
 OLA-21 Acinus of liver 213
 SN-46 Bare areas of liver 213
 SN-47 Lobes of liver 214
 LAQ-15 Liver 215
 LAQ-16 Head of pancreas 220
- 20. Kidney and Ureter 227**
- OLA-22 Name the nerves related to the posterior surface of kidney 227
 OLA-23 Give the relations of posterior surface of left kidney 227
 SN-48 Vascular segments of kidney 227
 SN-49 Psoas major 228
 OLA-24 Renal angle 229
 OLA-25 Floating kidney 229
 OLA-26 Pelvic kidney 230
 SAQ-9 Renal fascia 230
 LAQ-17 Kidney 231
 LAQ-18 Ureter 238
- 21. Suprarenal Gland and Chromaffin System 248**
- OLA-27 State the two developmental components of adrenal gland? 248
 OLA-28 What is the structure of adrenal medulla and what are its secretions? 248
 OLA-29 What is chromaffin reaction? 248
 OLA-30 Name the hormones secreted by suprarenal gland 249
 LAQ-19 Suprarenal gland 249
- 22. Diaphragm 256**
- OLA-31 Structures passing through the aortic opening of the diaphragm. 256
 OLA-32 Referred pain 256
 LAQ-20 Diaphragm 257
 OLA-33 Diaphragmatic hernia 262
- 23. Posterior Abdominal Wall 263**
- LAQ-21 Renal artery 263
 SN-50 Middle suprarenal artery 266
 SN-51 Testicular artery 267
 SN-52 Ovarian artery 270
- SN-53 Lumbar arteries 272
 SN-54 Common iliac arteries 274
 OLA-34 External iliac artery 276
 SN-55 Relations of external iliac artery 276
 SN-56 Branches of external iliac arteries 278
 SN-57 Superior vesical artery 280
 SN-58 Lateral sacral artery 281
 OLA-35 Tributaries of inferior vena cava 282
 LAQ-22 Inferior vena cava 283
 OLA-36 Cisterna chyli 287
 SN-59 Cisterna chyli 287
- 24. Perineum 289**
- OLA-37 Enumerate the structures piercing the perineal membrane in male ♂ 289
 SN-60 Perineal body (central perineal tendon) 289
 OLA-38 Attachments and nerve supply of external anal sphincter 291
 SN-61 External anal sphincter 291
 OLA-39 Boundaries of ischiorectal fossa 294
 OLA-40 Contents of ischiorectal fossa 295
 LAQ-23 Ischiorectal fossa 295
 SN-62 Pudendal canal (fascial canal, Alcock's canal) 297
 LAQ-24 Internal pudendal artery 298
 OLA-41 Structures piercing perineal membrane in female ♀ 304
 OLA-42 Perineal membrane 304
 SN-63 Urogenital diaphragm 304
 SN-64 Perineal membrane (inferior fascia of urogenital diaphragm) 306
 LAQ-25 Superficial perineal pouch 308
 LAQ-26 Deep perineal pouch 312
- 25. Urinary Bladder and Urethra 316**
- SN-65 Automatic bladder (neurogenic bladder, reflex bladder) 316
 OLA-43 What is the capacity of gallbladder and urinary bladder? 316
 OLA-44 Nerve supply of urinary bladder 316
 LAQ-27 Urinary bladder 317
 SN-66 Female ♀ urethra 323
 LAQ-28 Male ♂ urethra 325
- 26. Female ♀ Reproductive Organs 330**
- OLA-45 Prolapse of uterus 330
 SN-67 Prolapse of uterus 330
 LAQ-29 Ovary 331
 SAQ-10 Ovarian fossa 335
 LAQ-30 Uterine tube 335
 OLA-46 What is hysterosalpingography? 338
 SN-68 Applied importance of supports of uterus 338
 OLA-47 Abnormal positions of uterus 339

SN-69 Broad ligament of uterus 339
 LAQ-31 Uterus 340
 SN-70 Uterine artery 345
 SN-71 Middle rectal artery 348

27. Male Reproductive Organs 350

OLA-48 Median lobe of prostate 350
 LAQ-32 Prostate 350
 OLA-49 Benign prostatic hypertrophy 356

28. Rectum and Anal Canal 357

OLA-50 Prostatic urethra 357
 OLA-51 Urethral sphincters 357
 OLA-52 Internal anal sphincter 358

SN-72 Anal sphincters 358
 OLA-53 Mucosal folds of rectum 358
 LAQ-33 Rectum 359
 OLA-54 Blood supply of anal canal 364
 SN-73 White and pectinate lines of anal canal 364
 LAQ-34 Anal canal 364

29. Walls of Pelvis 370

OLA-55 Attachments to iliac spines 370
 SN-74 Internal iliac artery 370
 SN-75 Inferior vesical artery 373
 SN-76 Inferior gluteal artery 374
 SN-77 Iliolumbar artery 375

Index

377