

Textbook of **NEUROANATOMY**

with Clinical Orientation

is a well illustrated, easy to understand text that meets the requirements of undergraduate medical students. The book contains two sections, the first dealing with the central and the second with the peripheral nervous system.

Section 1: **Central Nervous System** includes a regional approach to the brain and spinal cord, highlighting the relevant clinical applications and presents a large number of well-labelled color diagrams to illustrate the text.

Section 2: **Peripheral Nervous System** has a well illustrated comprehensive chapter on the functional components of the cranial nerve nuclei. Clinically important topics have been elaborated.

A separate appendix **Glossary of Neuroanatomical Terms** will be of immense value to the students for revision of the neuroanatomical facts.

The book fully conforms to the latest competency-based syllabus prescribed by the Medical Council of India.

DR Singh MBBS, MS (Anatomy), PhD (Anatomy), FIANS, FFASI

is Emeritus Professor, Department of Anatomy, King George's Medical University, Lucknow, UP, and a well known anatomist of the country. He has been Professor and Head, Department of Anatomy, King George's Medical College, Lucknow. On deputation from Government of India, he also served as Professor and Head, BP Koirala Institute of Health Sciences, Dharan, Nepal.



Dr Singh dexterously combines meticulous teaching with outstanding research which has earned him 'Dr Dharam Narayan Memorial Gold Medal' for the best research paper presented from amongst the young anatomists at the annual conference of the Anatomical Society of India and 'Dr Mahdi Hasan Gold Medal' for presenting the best paper on clinical anatomy in 1979 and 1998, respectively. He has published 33 original publications in the indexed national and international journals with nearly 50 citations, and 4 international scientific presentations. In addition, he was awarded 2 orations: 'Prof Shamer Singh Memorial Oration' and 'Dr Sukhbir Prasad Jain Oration'. Medical Council of India conferred upon him the prestigious 'Hari Om Ashram Alembic Research Award' under the category of Basic Medical Sciences in 1997, for overall contribution to the field of anatomy. The Anatomical Society of India has recently conferred on him 'Dr Indarjit Dewan Lifetime Achievement Award' at the annual conference of the Society held in November 2019 at New Delhi.

Textbook of **NEUROANATOMY**

Singh



CBS Publishers & Distributors Pvt Ltd

4819/XI, Prahlad Street, 24 Ansari Road, Daryaganj, New Delhi 110 002, India
E-mail: delhi@cbspd.com, cbspubs@airtelmail.in; Website: www.cbspd.com
New Delhi | Bengaluru | Chennai | Kochi | Kolkata | Mumbai
Bhopal | Bhubaneswar | Hyderabad | Jharkhand | Nagpur | Patna | Pune | Uttarakhand | Dhaka (Bangladesh) | Kathmandu (Nepal)



QR code to access online CBS Catalogue

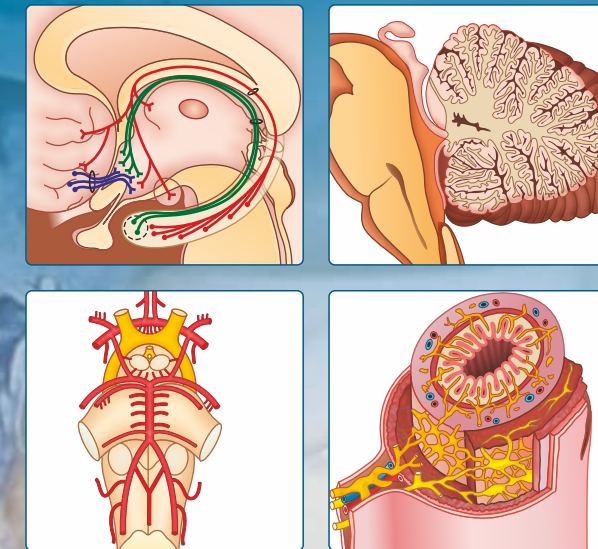
ISBN: 978-93-89688-50-4



9 789389 688504

Textbook of **NEUROANATOMY**

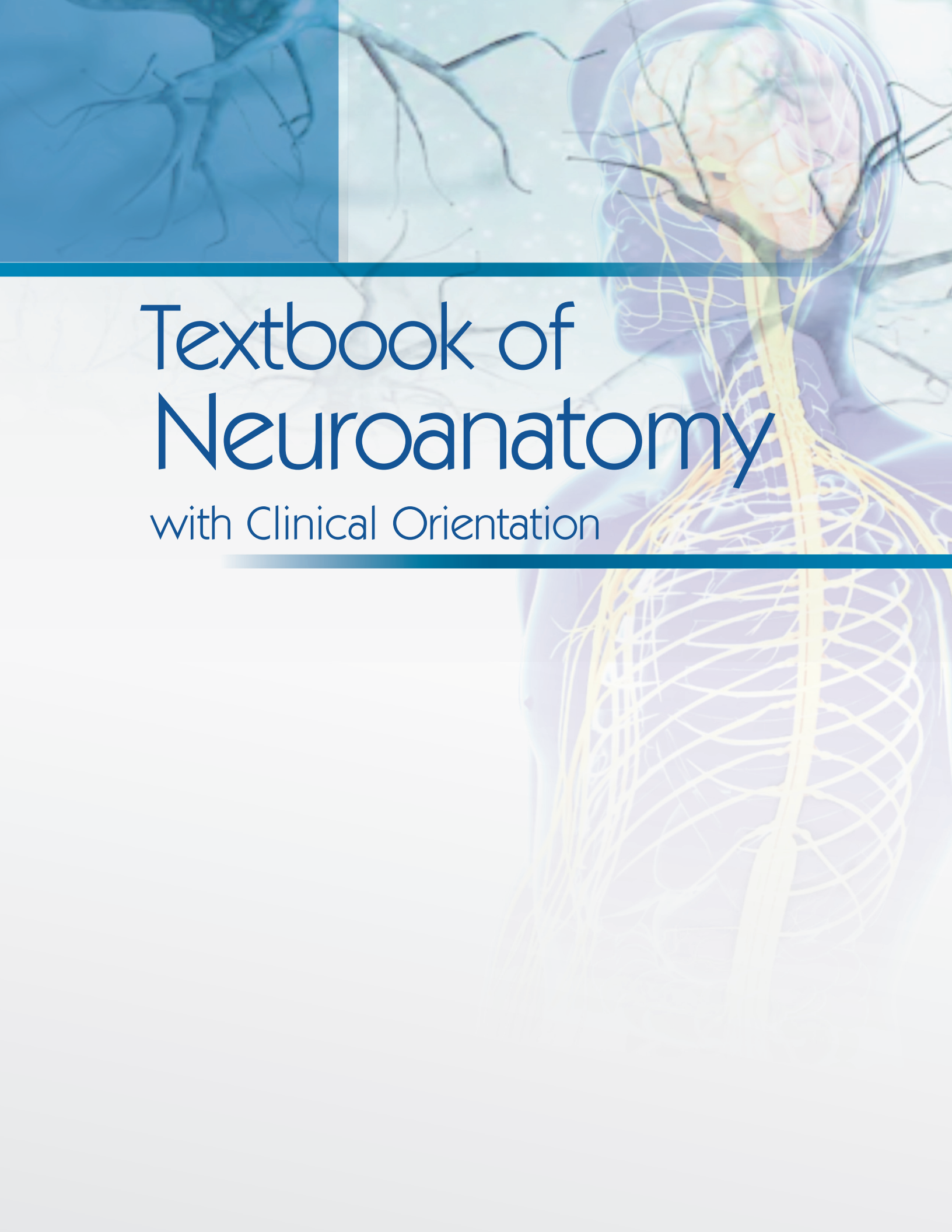
with Clinical Orientation



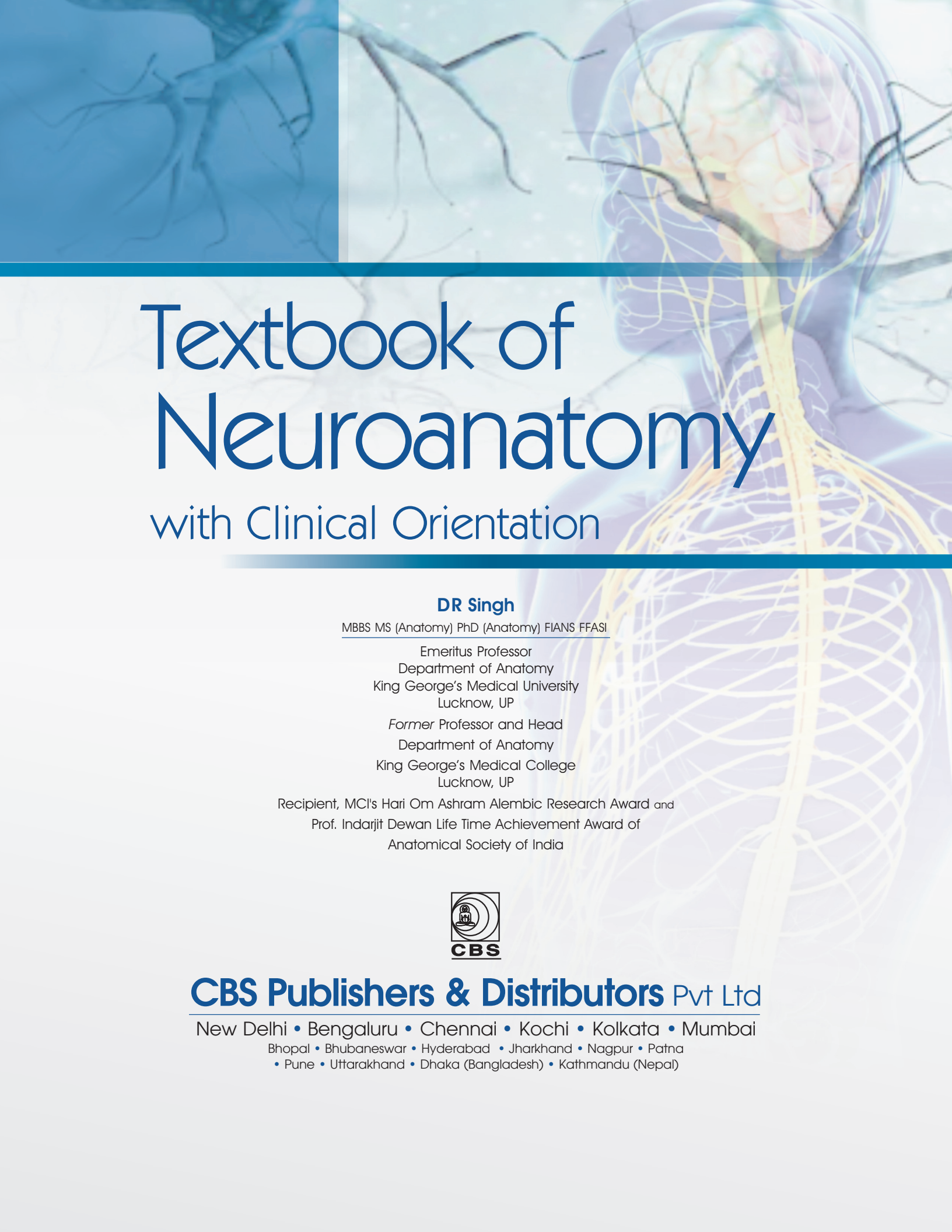
DR Singh



CBS Dedicated to Education
CBS Publishers & Distributors Pvt Ltd



Textbook of
Neuroanatomy
with Clinical Orientation



Textbook of Neuroanatomy

with Clinical Orientation

DR Singh

MBBS MS (Anatomy) PhD (Anatomy) FIANS FFASI

Emeritus Professor
Department of Anatomy
King George's Medical University
Lucknow, UP

Former Professor and Head
Department of Anatomy
King George's Medical College
Lucknow, UP

Recipient, MCI's Hari Om Ashram Alembic Research Award and
Prof. Indarjit Dewan Life Time Achievement Award of
Anatomical Society of India




CBS Publishers & Distributors Pvt Ltd

New Delhi • Bengaluru • Chennai • Kochi • Kolkata • Mumbai

Bhopal • Bhubaneswar • Hyderabad • Jharkhand • Nagpur • Patna
• Pune • Uttarakhand • Dhaka (Bangladesh) • Kathmandu (Nepal)

Disclaimer

Science and technology are constantly changing fields. New research and experience broaden the scope of information and knowledge. The author has tried his best in giving information available to him while preparing the material for this book. Although all efforts have been made to ensure optimum accuracy of the material, yet it is quite possible some errors might have been left uncorrected. The publisher, the printer and the author will not be held responsible for any inadvertent errors, omissions or inaccuracies.



ISBN: 978-93-89688-50-4

Copyright © Publisher and author

First Edition: 2020

All rights are reserved. No part of this book may be reproduced or transmitted in any form or by any means, electronic or mechanical, including photocopying, recording, or any information storage and retrieval system without permission, in writing, from the author and the publisher.

Published by [Satish Kumar Jain](#) and produced by [Varun Jain](#) for

CBS Publishers & Distributors Pvt Ltd

4819/XI Prahlad Street, 24 Ansari Road, Daryaganj, New Delhi 110 002

Ph: 011-23289259, 23266861, 23266867

Fax: 011-23243014

Website: www.cbspd.com

e-mail: delhi@cbspd.com; cbspubs@airtelmail.in

Corporate Office: 204 FIE, Industrial Area, Patparganj, Delhi 110 092

Ph: 011-4934 4934

Fax: 011-4934 4935

e-mail: publishing@cbspd.com; publicity@cbspd.com

Branches

- **Bengaluru:** Seema House 2975, 17th Cross, K.R. Road, Banasankari 2nd Stage, Bengaluru 560 070, Karnataka
Ph: +91-80-26771678/79 Fax: +91-80-26771680 e-mail: bangalore@cbspd.com
- **Chennai:** 7, Subbaraya Street, Shenoy Nagar, Chennai 600 030, Tamil Nadu
Ph: +91-44-26260666, 26208620 Fax: +91-44-42032115 e-mail: chennai@cbspd.com
- **Kochi:** 42/1325, 1326, Power House Road, Opp KSEB Power House, Eranakulam 682 018, Kochi, Kerala
Ph: +91-484-4059061-67 Fax: +91-484-4059065 e-mail: kochi@cbspd.com
- **Kolkata:** No. 6/B, Ground Floor, Rameswar Shaw Road, Kolkata-700014 (West Bengal), India
Ph: +91-33-2289-1126, 2289-1127, 2289-1128 e-mail: kolkata@cbspd.com
- **Mumbai:** 83-C, Dr E Moses Road, Worli, Mumbai-400018, Maharashtra
Ph: +91-22-24902340/41 Fax: +91-22-24902342 e-mail: mumbai@cbspd.com

Representatives

- | | | | | | |
|----------------------------|----------------|----------------------|--------------|-----------------------------|--------------|
| • Bhopal | 0-8319310552 | • Bhubaneswar | 0-9911037372 | • Hyderabad | 0-9885175004 |
| • Jharkhand | 0-9811541605 | • Nagpur | 0-9421945513 | • Patna | 0-9334159340 |
| • Pune | 0-9623451994 | • Uttarakhand | 0-9716462459 | • Dhaka (Bangladesh) | 01912-003485 |
| • Kathmandu (Nepal) | 977-9818742655 | | | | |

Printed at Nutech Print Services, Faridabad, Haryana, India

in loving memory of



(Late) Dr SHM Abdi

*Professor, Department of Anatomy
JN Medical College, AMU, Aligarh
my friend and colleague*

Preface

Neuroanatomy is essential, in particular, for the localization of the site of lesion in the neurological disorders. Much of the appreciation of the subjects of neurophysiology, neurology and neurosurgery depends upon a good knowledge of the anatomy of nervous system. To majority of medical students, however, neuroanatomy appears quite 'boring' and 'complicated' as well due to the fact that most of the nuclei, tracts, and connections, etc. described in almost every component of the nervous system are not visible to the naked eye. This sometimes can be more disappointing during the dissection of brain.

There are two categories of books available for the study of the neuroanatomy. First, is a large, standard reference book which treats mainly the detailed account of central and peripheral nervous systems contents. The second category of book is a very concise book made easy and simple, which focuses directly on the essential fundamentals, eliminating those aspects of the subject which have little clinical bearing and emphasize only those aspects of the different subdivisions of the extensive neuroanatomical literature which are of applied interest.

The *Textbook of Neuroanatomy* is intended to fall in the second category of books. It provides brief, up-dated and easy to understand neuroanatomy to the medical students in their undergraduate courses. In addition to the conventional central nervous system, dealing with different approach to the brain and spinal cord, the chapters in lecture notes included in the present book deal emphatically with the autonomic and enteric components of the nervous system that still remain largely unexplored. It cannot be too emphatically stated that the 'clear concepts' in neuroanatomy are only imaginative. Hence, a good understanding of these concepts make the neuroanatomy most interesting.

In preparing this book the text has been supplemented from the latest editions of standard books of the neuroanatomy and made an attempt to present the knowledge in a simplified form. The book has been designed to cover the subject in the minimal possible space keeping in mind the predicament of the already over-burdened medical students. No compromise has, however, been made when it came to the number of illustrations. Simple and self-explanatory line diagrams have been, therefore, liberally incorporated. The diagrams are largely based on the author's self-designed outlines assisted by the ones drawn by Prof Nafis Faruqui, JN Medical College, Aligarh. All efforts to have text diagrams simple and reproducible in the examination have been kept in mind wherever possible.

I feel confident that present textbook will be useful not only to the undergraduate students but also to the postgraduates and young faculty members interested to teach their students with this crucial part of the human anatomy. The mnemonics (designed to aid memory) and humor used in these lecture notes do not intend any disrespect for the original investigators, rather they are employed as an educational device—because as it is well known that the best memory techniques involve the use of simple associations (unfortunately not attempted more frequently) in medical education. The text hopefully will be useful reading before or during

the examination course, which will enable the students to rapidly revise overall facts about the clinical neuroanatomy.

I am conscious of my limitations and many errors might have escaped my scrutiny. Discerning readers are requested to inform me to my failings and forward me their critical comments as also their suggestions for improvement of the book.

DR Singh

Acknowledgments

The idea for writing this textbook was the constant suggestions from my present and former students. It is difficult to name all of them so I begin with expressing my gratefulness collectively. Indeed I learnt the subject of anatomy in general, and neuroanatomy in particular from my students of more than fifty years of my teaching. I should like to name a few of my former students, now colleagues, who were unhesitant in discussing with me their personnel teaching experiences.

I am indebted to Dr Punita Manik a devoted teacher and presently the Head, Department of Anatomy. Prof Anita Rani, of the department, has been very cooperative for any help I required during the preparation of this book.

It is a special pleasure to acknowledge the inspiration for hard work and constant encouragement which I received from YN Arjuna, Senior Vice President—Publishing, Editorial, and Publicity. He deserves my special thanks and sincere regards for his many helpful suggestions and whole heartedly cooperation throughout the completion of this book. I also appreciate the meticulous drawings made by Mr Ram Murti, Artist, CBS Publishers and Distributors Pvt Ltd, who worked extremely hard to finalize the illustrations, many of which were drawn initially by Prof. Nafis Faruqui, JN Medical College, Aligarh Muslim University, Aligarh.

The help rendered by Mr Mukund Kumar (Proofreader) and Mrs Jyoti Kaur (DTP Operator) is thankfully acknowledged for organizing the galley-proofs.

I put on records my full appreciation to my revered teachers in my alma mater, (Late) Prof Dharam Narayan, (Late) Prof AC Das, and (Late) Prof Mahdi Hasan who taught me anatomy during my undergraduate medical carrier.

Finally, I owe much to my life-partner Rekha, my children, and my daughter-in-law Supriya who always encouraged me in all my academic pursuits.

DR Singh

Contents

Preface

vii

Section I: Central Nervous System

1. Organs and Tissue of Central Nervous System	3
Organs of Central Nervous System	3
Brain	3
Spinal Cord	5
Spinal Segments	6
Structure of Nervous Tissue	6
Neuron	6
Microscopic Structure of Neuron	9
Ultrastructure of Neuron	11
Nucleus	12
Neuroglia	13
Astrocytes	13
Oligodendrocytes	14
Microglia	14
Ependymal Cells	14
Synapse	14
2. Development of Central Nervous System	17
Central Nervous System	17
Primary Brain Vesicles and Flexures	17
Further Development of the Brain Vesicles	18
Developmental Defects in Central Nervous System	20
Developmental Defects in Brain	21
Histogenesis of CNS	21
Myelination and Postnatal Development of Brain	22
3. Spinal Cord or Medulla Spinalis	25
Development of Spinal Cord	25
Normal Development	25
Abnormal Development	26
Gross Features of the Spinal Cord	28
Internal Structure of Spinal Cord Seen in Transverse Sections	28
TS at Different Vertebral Levels	30
Terminal or Fifth Ventricle	30
Nuclei in Spinal Grey Matter	31
Rexed's Laminae	32
Interneurons	33
Funiculi or Tracts in White Matter	33
Tracts in the Posterior Funiculus	34

Tracts in the Anterolateral Funiculus 34
Applied Anatomy of Spinal Cord 36

4. Brainstem

38

What is Brainstem? 38
Development 38
Components of Brainstem 39
Gross Features of Brainstem 40
Appearance from Front 40
Appearance from Back 40
Appearance from Sides 41
Cranial Nerve Nuclei in Brainstem 41
Tracts in Brainstem 41
Clinical Significance 44

5. Brainstem 1: Medulla Oblongata

45

Development of Medulla 45
External Features 45
Ventral Aspect 46
Dorsal Aspect 47
Lateral Aspect 47
Internal Structure 48
TS of Medulla at Lower Part—Pyramidal (motor) Decussation 48
TS of Medulla at Middle Part—Sensory Decussation 49
TS of Medulla at Mid-olivary Level 50
Functional Cell Columns in Brainstem 51
Nuclei and their Fibre-bundles 51
Clinical Significance of Blood Supply to Medulla Oblongata 53
Occlusion of Main Arteries Supplying Medulla 53

6. Brainstem 2: Pons

56

Development of Pons 56
Cranial Nerve Nuclei in Pons 56
Functions 57
External Features of Pons 57
Internal Structure of the Pons 59
Ventral or Basilar Part of Pons 59
Dorsal or Tegmental Part of Pons 59
TS through Lower Pons 59
TS through Upper Pons 61
Arterial Supply of Pons 61
Applied Anatomy and Clinical Significance of Pons 61
Lateral Pontine Syndrome or Marie-Foix Syndrome 62

7. Rhombencephalon 1: Cerebellum and Cerebellar Cortex

64

General Features 64
Morphological Subdivisions 65
Superior Surface 66
Inferior Surface 66

Functional Subdivisions	67
Flocculonodular Lobe	67
Corpus Cerebelli	67
Vestibulocerebellum (archicerebellum)	67
Spinocerebellum (paleocerebellum)	67
Neo- or Ponto-cerebellum	67
Development of Cerebellum	68
Gross Internal Structure	68
Grey Matter—Intracerebellar Nuclei	68
White Matter—Fibre Tracts	70
Afferent Fibres	70
Efferent Fibres	72
Microscopic Structure of Cerebellum	72
Layers in Cerebellar Cortex	72
Granular Layer	72
Purkinje Cell Layer	72
Molecular Layer	73
Connections of the Cerebellar Nuclei	73
Cortical Inputs and Outputs	74
Cortical Outputs	75
Functions of Cerebellum	75
Cerebellar Dysfunction	76
Localisation of Cerebellar Disease	76

8. Rhombencephalon 2: Fourth Ventricle and Area Postrema **77**

Development of Fourth Ventricle	78
Boundaries of Fourth Ventricle	78
Angles	78
Lateral Boundaries	78
Roof	78
Floor (Rhomboid fossa)	79
Recesses	81
Applied Anatomy	81
Area Postrema	81

9. Brainstem 3: Midbrain **83**

Development of Midbrain	83
External Features of Midbrain	84
From Dorsal Aspect	85
Internal Structure of Midbrain	87
Crus Cerebri	87
Substantia Nigra	87
TS at Inferior Collicular Level	87
TS at Superior Collicular Level	89
Arterial Supply of Midbrain	94
Midbrain Lesions due to Vascular Insufficiency	94
Blockage of Cerebral Aqueduct	94

- 10. Diencephalon 1: Thalamus, Metathalamus and Epithalamus** **96**
- Introduction to Forebrain 96
 - Development of Diencephalon 96
 - Parts and Functions of Diencephalon 97
 - Dorsal Thalamus 97
 - Parts of Thalamus 98
 - Nuclei of Thalamus 99
 - Connections of Thalamic Nuclei 100
 - Anterior Group Nuclei 101
 - Medial Group Nuclei 101
 - Lateral Group Nuclei and Pulvinar 101
 - Ventral Group Nuclei 101
 - Intralaminar Nuclei 102
 - Midline Nuclei 102
 - Reticular Nucleus 102
 - Metathalamus 103
 - Epithalamus 104
 - Habenular Complex 105
 - Pineal Body 105
 - Posterior Commissure 107
- 11. Diencephalon 2: Hypothalamus and Subthalamus** **109**
- Hypothalamus 109
 - Nuclei of Hypothalamus 109
 - Connections of Hypothalamus 110
 - Extrinsic Fibre Bundles 111
 - Fornix 111
 - Stria Terminalis 112
 - Stria Medullaris Thalami 112
 - Dorsal Longitudinal Fasciculus (of Schütz) 112
 - Medial Forebrain Bundle 112
 - Mammillary Peduncle 112
 - Intrinsic Fibre Bundles 112
 - Functions of Hypothalamus 112
 - Autonomic Control 112
 - Regulation of Body Temperature 113
 - Endocrine Functions 113
 - Regulation of Food and Water-intake 113
 - Reproduction and Sexual Behaviour 113
 - Biological Clock and Circadian Rhythms 114
 - Emotional Behaviour 114
 - Sleep, Wakefulness, Alertness and Excitement 114
 - Subthalamus or Ventral Thalamus 115
 - Nuclei of Subthalamus 115
 - Fibre Connections of Subthalamic Nucleus 115
- 12. Diencephalon 3: Third Ventricle and Circumventricular Organs** **117**
- Boundaries of Third Ventricle 117
 - Anterior Wall 117

Posterior Wall 118
Lateral Wall 118
Superior Wall or Roof 118
Inferior Wall or Floor 119
Communications of Third Ventricle 119
With Lateral Ventricles 119
With Fourth Ventricle 119
Recesses of Third Ventricle 119
Choroid Plexus and Tela Choroidea 120
Circumventricular Organs (CVOs) 120

13. Telencephalon 1: Convolutions and Functional Cortical Areas **122**

Gross Features of Cerebral Hemispheres 122
Lobes of Cerebral Hemisphere 123
Surfaces and Borders including Convolutions 124
Types of Sulci 128
Cortical Areas 128
Types of Homunculi 129
Functional Cortical Areas 129
Somatosensory Areas 132
Special Sensory Areas 133
Olfactory Areas 133
Taste Areas 133
Visual Areas 133
Acoustic Areas 134
Vestibular Area 134
Association Areas 134
Structure of Cerebral Cortex 135
General Features of Cerebral Cortex 135
Microscopic Structure of Cerebral Cortex 136

14. Telencephalon 2: White Matter or Fibre Tracts **138**

Association Fibres Tracts 138
Superior Longitudinal Fasciculus 138
Fronto-Occipital Fasciculus 139
Cingulum 139
Inferior Longitudinal Fasciculus 140
Uncinate Fasciculus 140
Perpendicular Fasciculus 140
Commissural Fibres 140
Corpus Callosum 140
Parts and Relations 140
Fibres of Corpus Callosum 141
Anterior Commissure 141
Hippocampal Commissure (Commissure of Fornix) 142
Projection Fibres 142
Internal Capsule 143
Arterial Supply of Internal Capsule 145

- 15. Telencephalon 3: Basal Nuclei of Cerebral Hemispheres** **146**
- Introduction to Basal Nuclei 146
 - Main Components of Basal Nuclei 146
 - Caudate Nucleus 147
 - Lentiform Nucleus 148
 - Corpus Striatum 148
 - Pallidum 149
 - Connections of Pallidum 150
 - Other parts of Basal Nuclei 150
 - Substantia Nigra 150
 - Subthalamic Nucleus 151
 - Arterial Supply of Basal Nuclei 151
 - Functions of Basal Nuclei 153
 - Motor Functions 153
 - Cognitive Functions 153
 - Clinical Disorders Affecting Basal Nuclei 154
- 16. Telencephalon 4: Lateral Ventricles and Choroid Plexuses** **156**
- Lateral Ventricles 156
 - Central Part or Body 156
 - Anterior or Frontal Horn 158
 - Posterior or Occipital Horn 158
 - Inferior or Temporal Horn 160
 - Choroid Plexuses of Lateral Ventricles 160
 - Choroid Fissure 161
 - Boundaries of the Choroid Fissure 161
 - Radiological Procedures related to Lateral Ventricles 161
 - Pneumoencephalography 161
 - Ventriculography 162
 - CT-Scan and Magnetic Resonance Imaging (MRI) 163
 - Age Changes 163
- 17. Meninges of Central Nervous System and Cerebrospinal Fluid** **164**
- Dura Mater 164
 - Cranial or Cerebral Dura Mater 164
 - Dural Septa (folds) 165
 - Nerve Supply 165
 - Dural Venous Sinuses 166
 - Spinal Dura Mater 167
 - Arachnoid Mater 167
 - Cerebral Arachnoid Mater 167
 - Spinal Arachnoid Mater 168
 - Pia Mater 169
 - Cerebral Pia Mater 169
 - Spinal Pia Mater 169
 - Subarachnoid Space and Cisterns 169
 - Subarachnoid Cisterns 169
 - Cerebrospinal Fluid (CSF) 171

Circulation of CSF 171
 Biochemical Composition 171
 Functions of CSF 172
 Clinical Significance 172
 Distribution of CSF 172
 Collection of CSF 173
 Hydrocephalus 173

18. Blood Supply of Central Nervous System **174**

Significance of Blood Supply to Brain 174
 Vertebrobasilar System 175
 Branches of Vertebral Artery 176
 Branches of Basilar Artery 176
 Internal Carotid System 177
 Branches of Internal Carotid Artery 178
 Circle of Willis (Circulus Arteriosus) 179
 Arterial Supply of Spinal Cord 181
 Anterior Spinal Artery 181
 Posterior Spinal Arteries 181
 Radicular Arteries 181
 Venous Drainage of Brain 182
 External (superficial) Veins 182
 Internal (deep) Veins 183
 Venous Drainage of Spinal Cord 183

Section II: Peripheral Nervous System

19. Cranial and Spinal Nerves **187**

Cranial Nerves 187
 Terminology 187
 Emergence on Brain Surface 188
 Classification 189
 Spinal Nerves 189
 Emergence from Spinal Cord 189
 Course and Distribution of a Typical Spinal Nerve 189
 Cervical Plexus 192
 Hypoglossal Nerve 192
 Nerve Impulse and its Conduction 193

20. Functional Components of Spinal and Cranial Nerve Nuclei **194**

Structure of Cranial Nerve Nucleus 194
 Motor and Sensory 194
 Functional Components of Nerves 195
 Development of Functional Components 195
 Functional Components in Spinal Nerves 196
 Functional Components in Cranial Nerves 196
 Purely Sensory Cranial Nerves (I, II, and VIII) 196
 Primarily Motor Cranial Nerves (III, IV, VI, and XII) 197

Mixed Cranial Nerves (both sensory and motor function) V, VII, IX, X, and XI Spinal 199

Mixed Cranial Nerves (V, VII, IX, X and XI) have both Afferent and Efferent Column(s) 199

- 21. Autonomic Nervous System: Overview and Subdivisions** **204**
- Introduction to Autonomic Nervous System 204
 - Subdivisions of Autonomic Nervous System 204
 - Sympathetic Nervous System 206
 - Parasympathetic Nervous System 206
 - Enteric or Intrinsic Nervous System 207
 - Groups of Autonomic Ganglia 207
 - Transmitters Released at Synapses 207
- 22. Sympathetic Division of ANS: Thoracolumbar Outflow** **208**
- Introduction 208
 - Preganglionic and Postganglionic Efferent Fibres 208
 - Ganglia in Sympathetic Outflow 209
 - Sympathetic Chain (Trunk) 209
- 23. Parasympathetic Division of ANS: Craniosacral Outflow** **216**
- Introduction 216
 - Parasympathetic Outflow 217
 - Cranial Nerves 217
 - Spinal Nerves 220
 - Cranial Parasympathetic Ganglia 221
 - Relationship to Sympathetic Nervous System 222
- 24. Autonomic Innervations of Important Vital Body Organs** **223**
- Autonomic Distribution 223
 - Branches to Cranial and Spinal Nerves 223
 - Branches to Nerve Plexuses 223
 - Branches to Skin 224
 - Innervations of the Heart 224
 - Thoracolumbar (Sympathetic) 224
 - Craniosacral (Parasympathetic) 225
 - Sensory Innervation of Heart 225
 - Cardiac Plexuses 226
 - Superficial Cardiac Plexus 226
 - Deep Cardiac Plexus 227
 - Innervations of the Lungs 227
 - Pulmonary Plexuses 227
 - Innervations of the Internal Organs 229
 - Branches to Blood Vessels 229
 - Control of Vessel Tone 230
 - Branches to Stomach and Intestine 230
 - Branches to Liver 231
 - Branches to Kidneys 231

Branches to Urinary Bladder	232
Branches to Genital Organs	233
25. Enteric (Intrinsic) Nervous System: Second or GIT Brain	235
Introduction to Enteric Nervous System	235
Development	235
Extent and Location	236
Autonomic Components in Intrinsic Plexuses	237
Parasympathetic	237
Sympathetic	237
<i>Glossary of Neuroanatomical Terms</i>	<i>241</i>
<i>Index</i>	<i>259</i>

