



Chest X-Rays *for Medical Students* with Clinical Tutorials

provides a complete solution of chest X-ray reading, beginning from the basics including radiographic anatomy, quality assessment of the radiograph, important radiological signs to the range of clinical conditions commonly encountered in clinical practice. The radiological signs are correlated with clinical presentation of the diseases which will help undergraduate students, postgraduate residents of general medicine, pulmonary medicine, cardiology fellows and practicing physicians for better understanding of the subject. The text is generously illustrated with simple line diagrams to support chest X-rays. This will help the medical students and practitioners to ace chest X-ray diagnosis in a systematic manner.

Satyam Chaurasia completed his MBBS from Shri BM Patil Medical College, Hospital and Research Centre, Karnataka. He has worked in the regional tuberculosis centre under Madhya Pradesh government. Currently, he is postgraduate resident in Netaji Subhash Chandra Bose Medical College, Jabalpur, Madhya Pradesh.



ISBN: 978-93-5466-232-4

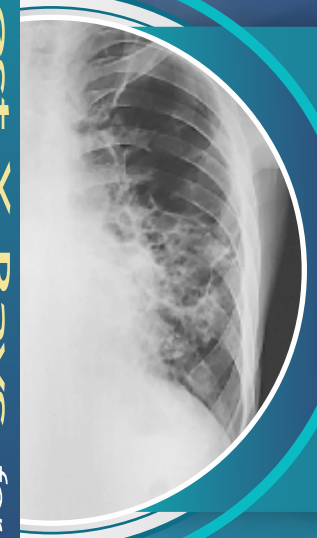

9 789354 662324

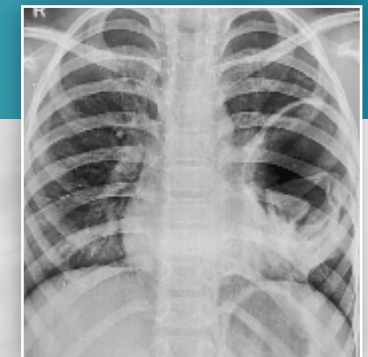
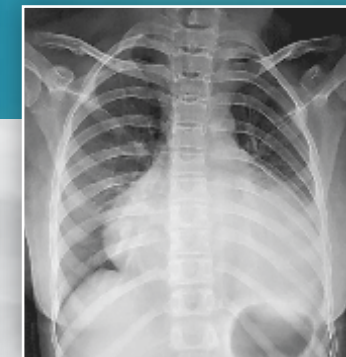
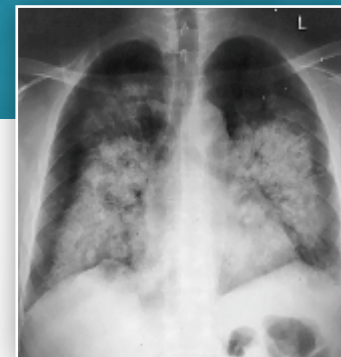
Dedicated to Education
CBSPD
CBS Publishers & Distributors Pvt Ltd
4819/XI, Prahlad Street, 24 Ansari Road, Daryaganj, New Delhi 110 002, India
E-mail: delhi@cbspd.com, customercare@cbspd.com; Website: www.cbspd.com
New Delhi | Bengaluru | Chennai | Kochi | Kolkata | Lucknow | Mumbai
Hyderabad | Jharkhand | Nagpur | Patna | Pune | Uttarakhnad

Chest X-Rays *for Medical Students*

Chaurasia



Chest X-Rays *for Medical Students* with Clinical Tutorials



Satyam Chaurasia



Dedicated to Education

CBS Publishers & Distributors Pvt Ltd



Contents

<i>Preface</i>	<i>vii</i>
PART 1: Basics	1
Introduction	1
Label	1
View	1
Density	2
Quality of CXR Film	2
Criteria for penetration	2
Criteria for rotation	2
Criteria for good inspiratory effort	2
Chest X-Ray [PA and AP View]	3
Clavicle	7
Anterior and Posterior Ribs	7
Scapula	7
Trachea	7
Mediastinal Space	7
Right and Left Lungs	8
Costophrenic Angle	8
Cardiophrenic Angle	11
Mediastinal Shadow	11
Hilar Shadow	12
The Diaphragm [PA View]	13
Chest X-ray [Lateral View]	13
Retrosternal and Retrocardiac Space	15
Pulmonary Artery	15
Posterior Costophrenic Angle	16
Mediastinal Masses	16
Esophagus	16
The Diaphragm (Lateral View)	17
Bronchopulmonary Segments	17
Hypertrophy Signs	18
Left ventricle hypertrophy	18
Left atrium hypertrophy	18

Right ventricle hypertrophy	18
Right atrial hypertrophy	19
Lung Disease Pattern	20
Interstitial disease pattern	20
Air space disease pattern	20
Honeycombing	20
Miliary	21
Opacity	22
Lung Collapse	22
Radiological Signs	24
Silhouette sign	24
Air bronchogram sign	26
Kerley A, B, C lines	26
Extrapleural sign	28
Canon ball metastases	29

PART 2: Chest X-Rays**31**

Pleural Effusion	31
Hydropneumothorax	33
Pneumothorax	34
Lung Abscess	36
Hydatid Lung Disease	37
Chronic Obstructive Pulmonary Disease	38
Consolidation Pneumonia	42
Bronchopneumonia	44
Bronchogenic Carcinoma	45
Interstitial Lung Disease	46
Pulmonary Embolism	48
Tropical Eosinophilia	49
Homogeneous Opacity of Lung	50
Mediastinal Adenopathy	53
Pericardial Effusion	54
Pulmonary Edema	55
Coin Lesion	59
Pneumoperitoneum	61
Sarcoidosis	62
Cardiomegaly	63

Dextrocardia	64
Bronchiectasis	65
Scoliosis	67
Right Ventricular Hypertrophy	67
Mitral Valve Disease	68
Lung Collapse	70
Foreign Body	72
Empyema	73
Subdiaphragmatic Abscess	74
Pleural Calcification	75
Aspergilloma	75
Coronavirus Disease	76
Pneumomediastinum	77
Emphysematous Bullae	78
Aneurysm of Aorta	78
Tuberculosis—Fibrotic Lesion	79
Tuberculosis—Miliary	81
Tuberculosis—Cavitation	81
Tuberculosis—Healed	82
Appendix	83
Primary Tuberculosis	83
Secondary Tuberculosis	83
ICU Medicine	84
Proper position of lines, tubes, and catheters	84
Index	85